Management of Bone Metastases

A Multidisciplinary Guide

Vincenzo Denaro
Alberto Di Martino
Andrea Piccioli
Editors

Springer

Management of Bone Metastases

Vincenzo Denaro • Alberto Di Martino
Andrea Piccioli
Editors

Management of Bone Metastases

A Multidisciplinary Guide

Springer

Editors
Vincenzo Denaro
Department of Orthopaedics and Trauma Surgery
University Campus Bio-Medico of Rome
Rome
Italy

Alberto Di Martino
Department of Orthopaedics and Trauma Surgery
University Campus Bio-Medico of Rome
Rome
Italy

Andrea Piccioli
General Direction of Health Program
National Ministry of Health of Italy
Rome
Italy

ISBN 978-3-319-73484-2 ISBN 978-3-319-73485-9 (eBook)
https://doi.org/10.1007/978-3-319-73485-9

Library of Congress Control Number: 2018943688

Printed on acid-free paper

This Springer imprint is published by the registered company Springer International Publishing AG
part of Springer Nature
The registered company address is: Gewerbestrasse 11, 6330 Cham, Switzerland

Foreword

Improving the success of anticancer therapies in recent decades has led to a marked prolongation of survival in patients suffering from cancer even in advanced disease. In this extended survival, many patients face persistent lesions or recurrences at the original or distant sites, and the skeleton as a whole is the third most frequent organ affected by distal metastases after the lungs and liver. Bone involvement frequently and seriously affects the life of the patients since it can cause severe pain and functional impairments; in addition, cancer therapy itself can alter bone composition. There is a need of therapies aimed at least at managing these aspects even when an effect on survival is not expected. It is also a public health matter since the burden of disease associated with bone metastases affects a wide population of cancer patients and consumes a relevant amount of health system resources; therefore, the selection of alternative therapeutic options should be based on solid knowledge. This manual provides an updated overview on the management of bone metastases, which is also clear and comprehensive, proposing an integrated multidisciplinary approach which is being more and more deemed as the most appropriate in many neoplastic diseases. The book covers several aspects of what is known about bone metastasis including basic science, *e.g.*, bone physiology and mechanisms determining homing and growth of tumor cells. Chapters address the different types of therapies, drugs, surgery, and physical agents, and also rehabilitation and possible complications are not neglected. Considerable attention is paid to the process of therapeutic decision, which is particularly important and complex in this field where most of the cases are not treated with curative intent but rather to limit the symptoms of the evolving disease and to ensure a better quality of the residual life. This book provides a description of evidence available, decisional algorithms, and software to assist in the complex path of clinical decision which has to be taken at an individualized level, considering clinical status and expected survival to balance the impact of therapies and benefits expected. Much attention is dedicated to orthopedic surgery, which has a key role in the management of bone metastases with several possible solutions and materials extensively described in the book. As it would be expected, several authors from well-known centers contributed to write a manual dealing with such a broad range of topics.

In conclusion, the editors make available to oncologists in general and to those specialized in the treatment of cancer bone metastases a valuable tool to assist them in the clinical management of such conditions.

Walter Ricciardi
President of the
Italian National Institute of Health
Rome, Italy

Preface

It has been estimated by AIRTUM (Italian Association of Cancer Registries) that there have been about 369,000 new diagnoses of cancer in Italy in 2017, approximately 192,000 males and 177,000 females. Overall, there are 1000 new diagnoses of cancer every day. These data are in line with those of the American Cancer Society (ACS), which estimates an incidence of 1.7 million new cases of cancer, half of which are prone to develop bone metastases. Despite the increased incidence, an increase in the survival of these patients has been observed in the last few years. According to the ACS, the 5-year overall survival of cancer patients has improved from 49% in the years 1975–1977 to 69% in the period 2006–2012. This outstanding result is due to the improvement in the integrated approach to the cancer patient.

Bone is the most common site for metastasis, mainly because of the contribution of breast and prostate cancers, which in postmortem examinations have showed a 70% prevalence of metastatic bone disease. However, bone metastases may occur in a wide variety of bone malignancies, with considerable morbidity and complex demands on healthcare resources. On the basis of the data of the Medical Expenditure Panel Survey (MEPS), the agency for healthcare research and quality estimated that the direct medical costs for cancer in the USA in 2014 were 87.8 billion dollars. Fifty-eight percent of those costs were for hospital outpatient or office-based visits and 27% were for inpatient hospital stays.

In fact, even though most cases of bone metastases are asymptomatic, these can cause pain and are complicated by the so-called skeletal-related events (SRE), which include pathologic fractures and impending fractures, spinal cord compression, and hypercalcemia. Therefore, the occurrence of a skeletal metastasis represents a severe event which negatively affects the prognosis of the cancer patient, above all if the lesion requires surgery. On average, a patient with metastatic disease will experience SREs once every 3 to 6 months, usually clustering around periods of progression of the disease, and becoming more frequent as the disease becomes more extensive. Moreover, occurrence of SREs is associated with an increase in the frequency of invasive procedures and in the number of outpatient and daycare visits of the oncologic patient.

This book aims to develop awareness of the need for an integrated approach to patients affected by bone metastases, by presenting major advances in medical, surgical, and radiological interventions for patients with metastatic cancer to the bone. Moreover, the approach to the cancer patient in terms of

characterization of the patient's disease is fully discussed. The book consists of five parts, different in terms of contents and perspective with respect to the management of the bone cancer patient.

Part I is entitled “biology of bone metastases” and is devoted to the characterization of the pathology of bone metastasis, and to the medical treatments available today for patients with bone metastases, including bone modifying agents and anticancer agents with bone effects, and the bone-targeted therapies used in the adjuvant setting.

Part II is devoted to the “approach to the patients” affected by bone metastases, by giving guidelines to the clinician on how to characterize the single patient affected by bone metastases. In particular, some of the most difficult challenges for clinicians, like the determination of the patient's survival and the risk of fractures of bone lesions (the so-called impending fractures), are presented in a complete fashion. These issues influence most of the current work of oncologists, clinicians, and surgeons and represent the main issues in the care of the oncologic patient with metastatic disease to the bone. Current standards of radiation therapy to the long bones, pelvis, and spine are presented here indicating how this kind of treatment is currently crucial to the management of bone cancer patients. Finally, the guidelines of treatment of patients with metastases to the different bone segment (namely spine, long bone, and pelvis) are provided in separate chapters. We are extremely proud of this work, since it reflects the efforts of the Italian Orthopaedic Society (SIOT) Bone Metastases Study Group that in the last few years has drawn simple and reproducible criteria for decision-making in the clinical setting of the bone metastatic patient.

Part III deals with the surgical management of patients with bone metastases. In the last few years the development of newer instrumentation systems and biomaterials, together with less aggressive anesthesiological care, is reflected in more targeted surgery, and when possible with more aggressive surgery, even in the metastatic patient. This makes sense thinking of the increased survival time after surgery of the patients with metastases to the bone; therefore the implants and surgical techniques should be targeted to anatomical location, type of tumors, sensitivity to radiation, and adjuvant therapies, and above all to patients’ survival. Many chapters are dedicated to the complications more commonly associated with these surgical interventions. In particular, infections, fractures, and failures around tumor implants are among the most feared complications that can occur in these patients. Two outstanding contributions are devoted to the correct staging and preoperative planning of patients before surgery—“Think, stage, then act” is a simple but quintessential rule!—and to the common pitfalls occurring in the management of patients affected by skeletal metastases, which most often determine the final surgical results. A full chapter is dedicated to the rehabilitation of patients operated on for metastatic disease to the bone, since after the management of pain and disability, the return to function is our main aim for these patients.

Dealing with immunocompromised patients, or when the expected survival is not enough to accept the risks associated with surgical interventions, surgery is sometimes not an option for patients affected by metastases to the

bone. In this context, clinicians and interventional radiologists have developed newer minimally invasive techniques to manage these patients. This is the main topic of Part IV. In this context, other techniques like electrochemotherapy have been introduced into clinical practice in controlled studies and are now available to clinicians for the management of selected patients with bone metastases.

We end this book with a look to the contemporary directions in the management of bone metastases—what's new—and to the potential future directions of this discipline. We particularly thank Prof. Capanna for his visionary contribution to this book with his chapter entitled "Future Directions," which represents a leap into the next generation of treatments for patients affected by bone metastases.

We wish to thank our contributors for the outstanding work expressed in their respective chapters. They are well-known leading specialists worldwide in the topic of metastases to the bone and osteoncology, and we trust that this textbook will represent an international reference in the field of bone metastases. We do recognize that, given the rate of advancement of the knowledge in this field, some topics will need constant revision and update. However, today this textbook represents a collection of the most current knowledge on this subject and definitely reflects the tremendous advancements in the standard care of these patients worldwide.

Rome, Italy

Vincenzo Denaro
Alberto Di Martino
Andrea Piccioli

Contents

Part IV Minimally Invasive Tumor Treatment

Part V Future Directions

About the Editors

Vincenzo Denaro has been Full Professor in orthopaedic surgery and Dean at the University Campus Bio-Medico of Rome, and is one of the leading spine surgeons in Italy. His training included Professor Boni in Pavia, Professor Roy-Camille at the Hopital Pitie Salpetriere in Paris, and Prof. Macnab in Toronto. Being one of the founder members of the Cervical Spine Research Society of Europe, he has been President of the Italian Spine Society. His main fields of interest include the management of patients affected by spinal and tumour diseases. He is co-author of the National Guidelines on the management of bone metastases of the Italian Orthopaedic Society (S.I.O.T.), and of the Italian Association of Medical Oncology (A.I.O.M). He is author of more than 300 papers and book chapters, and has edited two books.

Alberto Di Martino is Assistant Professor in orthopaedics and trauma surgery at University Campus Bio-Medico of Rome. His main fields of interests include spine and tumour surgery, and basic research. He has a PhD in tissue regeneration in Orthopaedics, and is currently involved in the osteoncology unit at the University Campus Bio-Medico of Rome. His training included a Spine research fellowship at Thomas Jefferson University and the Rothman Institute of Philadelphia (USA), and is currently involved in the Spine and Oncology programs with Prof. Vincenzo Denaro at the University Campus Bio-Medico of Rome. He is the Editorial Coordinator of the Italian Orthopaedic Society Bone Metastasis Study Group of the Italian Orthopaedic Society (S.I.O.T.). He has authored more than 80 manuscripts, and is co-author of the National Guidelines on the management of bone metastases of the S.I.O.T., and of the Italian Association of Medical Oncology (A.I.O.M). He currently is board member of several leading journals in the fields of spine and orthopaedics.

Andrea Piccioli is an orthopaedic surgeon skilled in musculoskeletal oncology, trained at the Memorial Sloan Kettering Cancer Center of New York. He is the Secretary of Italian Society of Orthopedic and Traumatology (S.I.O.T.) and the Coordinator of the Working Group on Bone Metastasis of the Italian Society. He has been Orthopaedic Oncologist Consultant in "Palazzo Baleani" of Policlinico Umberto I in Rome, and is currently member of the Scientific Committee of the "Istituto Superiore di Sanità". He is the Director of the 3rd Office for Quality, Clinical Risk and Hospital Program, General Direction of Health Program, National Ministry of Health. He is the author of several scientific papers in the field of orthopaedic oncology and traumatology, and he is also responsible for the S.I.O.T. National Guidelines on Orthopaedic oncology. His main interests are on musculoskeletal oncology, and public health.

Metastases to the Pelvis

15

Eduardo J. Ortiz-Cruz, Manuel Peleteiro-Pensado, Irene Barrientos-Ruiz, and Rafael Carbonell-Escobar

Abstract

The optimal surgical treatment of bone metastases may be complex and require multimodality treatment strategies to achieve optimal outcomes. We describe the surgical indications of these patients, mainly in the periacetabular zone.

15.1 Introduction

Metastatic bone disease (MBD) to the pelvis is a challenging problem that affects the patient's quality of life (QOL) and is more frequently encountered by orthopedic surgeons. Pelvic metastases cause pain, pathologic fractures, and limit the ability to ambulate independently. Due to the relatively large dimension of the pelvic cavity, tumors at that location usually reach a significant size before symptoms appear.

Some locations of metastases within the pelvis have no important impact on pelvic stability and function (e.g., ilium and pubis), but tumors located at the posterior ilium may carry a risk for lumbosacral integrity, and tumors of the acetabulum may impair the hip function and the weight-bearing of extremity. Engagement of the acetabular region entails a major risk for pathological fracture due to the high mechanical loads.

The optimal treatment of bone metastases may be complex and require multimodality treatment strategies to achieve optimal outcomes, and these patients need multidisciplinary approach.

15.2 Treatment Planning

The selected procedure should offer an adequate treatment to the patient in order to achieve the best possible quality of life (QOL) while eluding an under- or overtreatment. Factors associated with poor QOL include loss of limb function, being bedridden, *and* the occurrence of pathologic fractures. There are three types of treatment: nonoperative treatment, minimally invasive palliative procedures, and surgical treatment.

The treatment depends on the patient's symptoms, prognosis, patient class [1], histological type, and the site of the metastasis, bone loss, performance status, patients, and family goals.

15.2.1 Minimally Invasive Palliative Procedures

Radiation therapy is effective in providing relief from painful bone metastasis with a global pain response rate as 60%, and therefore the external

E. J. Ortiz-Cruz (✉) · M. Peleteiro-Pensado · I. Barrientos-Ruiz · R. Carbonell-Escobar
Orthopaedic Oncology Unit, Orthopaedic Surgery Department, Hospital Universitario La Paz, Madrid, Spain
e-mail: rcarbonell@alumni.unav.es

V. Denaro et al. (eds.), *Management of Bone Metastases*, https://doi.org/10.1007/978-3-319-73485-9_15

irradiation is the standard care for patients with localized bone pain and palliation of the majority of these patients [2, 3].

However, patients who have recurrent pain at a site previously irradiated may not be eligible for further radiation therapy, and if they are not candidates for surgery, the advances in interventional radiology add to our armamentarium a palliative treatment of their symptoms [4].

The most frequent techniques are radiofrequency ablation, microwave ablation, cryoablation, and cementoplasty, which could be used in combination with the previous techniques [5–10].

15.2.2 Surgical Treatment

Surgical management of MBD is typically reserved for lesions with the highest risk of fracture and some solitary metastases. Curative resection is rare for bone metastasis, except for selected patients with isolated involvement; MBD requires mainly a palliative approach.

Although these procedures have a high rate of complications, the improvement of the quality of life could justify the surgical risks [11].

15.2.2.1 We Need to Know

The management of pelvic tumors is a challenge for orthopedics oncologists due to the complex anatomy of the pelvis and the need to have extensive exposures. The decision to proceed with surgery can be difficult for the clinician and the patient, as the risks of surgery may outweigh the expected benefits of improvement in pain and function.

The surgeon needs to understand the next issues and allow to answer some questions that are formulated in the next paragraphs:

- Comprehend the anatomic classification by Enneking. This classification is based on the resected region of the pelvis: type I, ilium; type II, periacetabular; type III, pubis; and resection of sacrum type IV resection [12] (Fig. 15.1).
- Comprehend the patients "classes," which are essential to distinguish which patients require a surgical treatment. Capanna and Campanacci [1] introduced a protocol in long bone metastases, which provide an aim to look for a suitable treatment and working for pelvic metastases too. The patients were divided into four classes: (1) solitary lesion with good prognosis, (2)

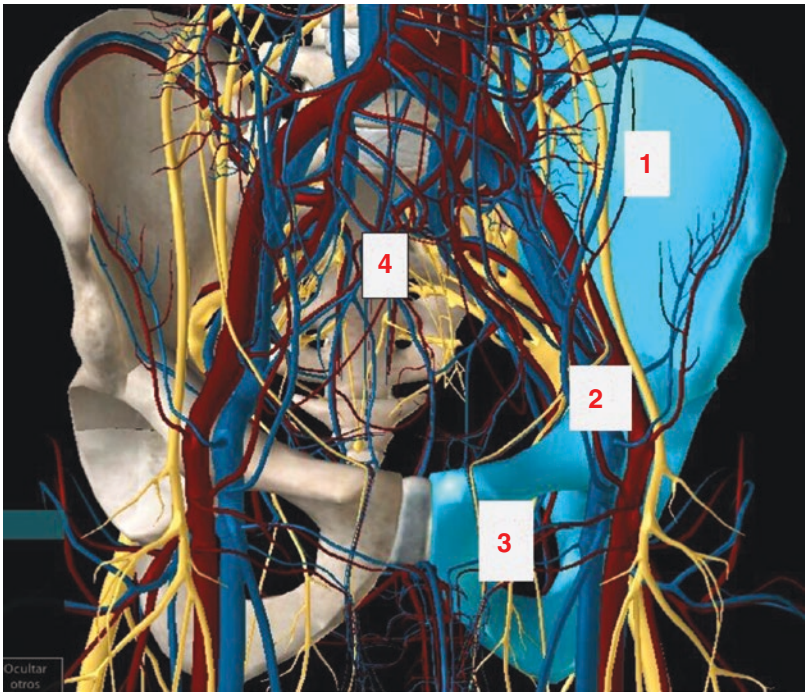

Fig. 15.1 Anatomic classification by Enneking. Type I, ilium; type II, periacetabular; type III, pubis; and type IV, sacrum resection

pathologic fracture, (3) impending fracture, and (4) osteoblastic lesions at all sites; osteolytic or mixed lesions in non-weight-bearing bones such as the fibula, ribs, sternum, or clavicle; osteolytic lesions in major bones with no impending fracture; and lesions in the iliac wing, anterior pelvis, or scapula.

Patients included in classes 1, 2, and 3 should have been referred to oncology orthopedic surgeon for possible surgical treatment. Class 4 patients are treated mainly conservatively by chemotherapy, hormonotherapy, and/or radiation therapy. Diphosphonates, narcotic analgesia, radiation therapy, and protected weight-bearing are the first steps in this nonsurgical management. The radiotherapy should not be indicated before surgery because of problems with wound healing that can occur.

– Recognize the zones of the pelvis those are at risk for mechanical failure and require surgery.
  - According to Muller and Cappanna, zones 1 and 3 are comparable to non-weight-bearing and expendable bones of the extremity (clavicle, sternum, and fibula). Zone 2 equals to the articular part of long bones (humerus, femur, and tibia), and those are the lesions with a high risk for mechanical failure.
  - Metastatic lesions in zones 1 and 3 (pubic rami, ischia, iliac wings) do not compromise the mechanical stability of the pelvic ring, and most of them don't require surgery and are not amenable to reconstruction. Patients with lesions in these locations often are managed with nonoperative treatment, in the form of medical and radiation therapy or with resection only. In contrast, the condition of patients with metastatic lesions about the acetabulum that result in progressive functional pain, hip protrusion, pathologic fracture, and inability to ambulate often is improved by operative reconstruction [13].
– Patient prognosis and an estimation of survival will help dictate the best treatment indication [14, 15].
– It is important to understand the metastatic acetabular classifications described by Harrington [16] and Issack et al. [17] in order to select the best type of surgical management.
  - Nonetheless, there is significant risk of morbidity and mortality that had to take in mind. Wood and coworkers [18] accomplished a systematic review of the literature in patients with MBD to the long bones and/or pelvis/acetabulum treated surgically, and they found a surgical advantage if the surgery is done and well indicated.
  - If the indication for surgery is made, which type of surgery is the best for the patient? What type of margin and what type of reconstruction? Regard which resection has to be indicated, after analysis of the literature; there are few data available to compare the outcome of wide resection and intralesional resection for pelvic metastases.
  - Ruggieri et al. [19] evaluate the role of intralesional/marginal resection compared to wide resection, and they didn't found difference in survival between wide resection and intralesional/marginal resection even in patients with solitary metastases. However, if the wide margin and reconstruction is suitable for the patient with solitary metastases, this indication is probably the best option in order to attempt to increase the survival mainly if the metastases are coming from thyroid and renal carcinomas. Preoperative embolization of these tumors is strongly recommended to reduce intraoperative blood loss.

15.2.3 Surgical Planning

Surgeries are rarely required for complete or impending pathologic fractures of the pelvis other than for those involving the acetabulum.

Surgical resection of the metastatic disease of the acetabulum should fulfill three aims:

1. Tumor resection
2. Bone defect reconstruction
3. Stabilization of the skeletal segment

15.2.4 Periacetabular Defects

Periacetabular tumors may cause severe debilitating pain with hip dysfunction and pathologic fractures often lead to protrusion acetabuli (Fig. 15.2). Small metastatic lesions to the acetabulum may be managed by radiation alone and intralesional resection to strengthen the acetabular roof and cement packing augmentation reinforcement with Steinman pins, or the use of a hip or pelvic prosthesis [20], and also with percutaneous bone packing. Bone cement raises the resistance of the acetabulum and allows loading of the limb (Fig. 15.3a, b).

When larger lesions have an intact medial wall but have significant acetabular defect, they can be reconstructed with a total hip arthroplasty augmented by cement and screws fixation.

Surgery is required for those lesions that compromise the load transfer from the lower limb to spine. These lesions affect the superior and medial acetabular walls, as well as the medial column of the pelvis and the posterior ilium in the region of the sacroiliac joint.

– Posterior ilium lesions not involving the acetabulum can be treated by intralesional resection and cement reconstruction (Fig. 15.3b).

Fig. 15.2 AP radiograph of a 72-year-old male that shows protrusion acetabuli, secondary by thyroid cancer, with hip pain since 3 months ago. Probably he needed a previous surgery, before protrusion acetabuli were identified

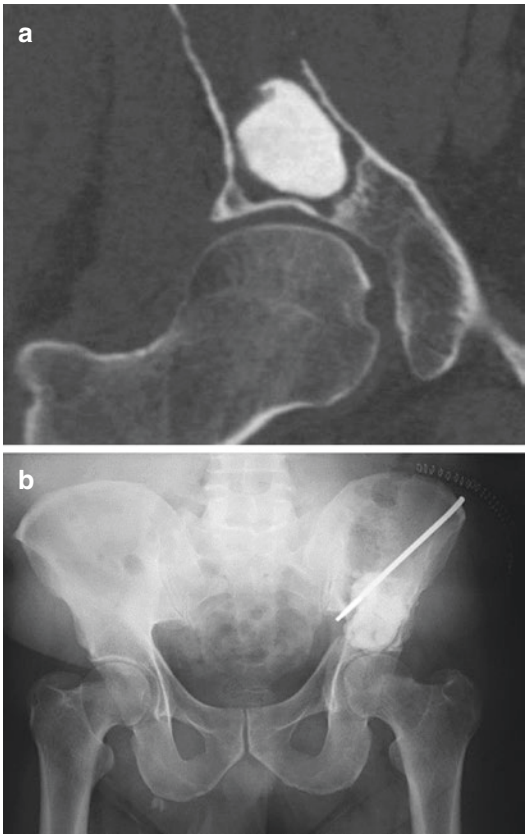

Fig. 15.3 AP radiographs that show percutaneous bone packing (**a**) and open intralesional resection and bone packing reinforced with a Steinman pin (**b**)

– Acetabular lesions that are contained (with an intact medial wall) can be reconstructed by a cemented arthroplasty. Protrusio acetabular cups compensate for deficiencies of the medial wall (MEC: Type 2), while cement and pin fixation (modified Harrington method) can be used effectively to reconstruct large defects in the acetabular column and dome (MEC Type 1 and 2) [21].
– In addition to classified metastatic disease of the acetabulum, Harrington described the surgical technique of reconstructing the pelvic ring with multiple pins, cement, cage, and a cemented total hip replacement. Since then, the method has been validated, and modifications of the technique have been proposed [22].
– A long-stem femoral component is often used, not just to complete the total hip reconstruction but also to prevent against pathologic fracture of the femur in the case of disease

progression. However, long cemented femoral stems may lead to adverse events such as hypotension or desaturation that are thought to be secondary to embolic phenomena.

– Cemented components are commonly favored in the setting of metastatic bone disease, as the associated use of radiation therapy will limit the degree of bony ingrowth with noncemented prostheses.

Type 3 and 4 may require resection or reconstruction with an acetabular prosthesis. Stemmed acetabular implants (ice cream cone prosthesis or pedestal cup) allow anchorage of the acetabular cup into the posterior ilium with the stem (Fig. 15.4a, b). Modular tumor prostheses are being increasingly used.

Alternatively, a custom made pelvic prosthesis may be used and joint reconstruction using bone allografts; however, they are burdened with a high rate of complications.

If the acetabulum is not possible to reconstruct, but a significant amount of iliac crest is available, a saddle prosthesis implant can be used, which acts as a yoke type device using the iliac crest as a fulcrum. These devices can fail by dislocation or by fracture of the remaining iliac crest.

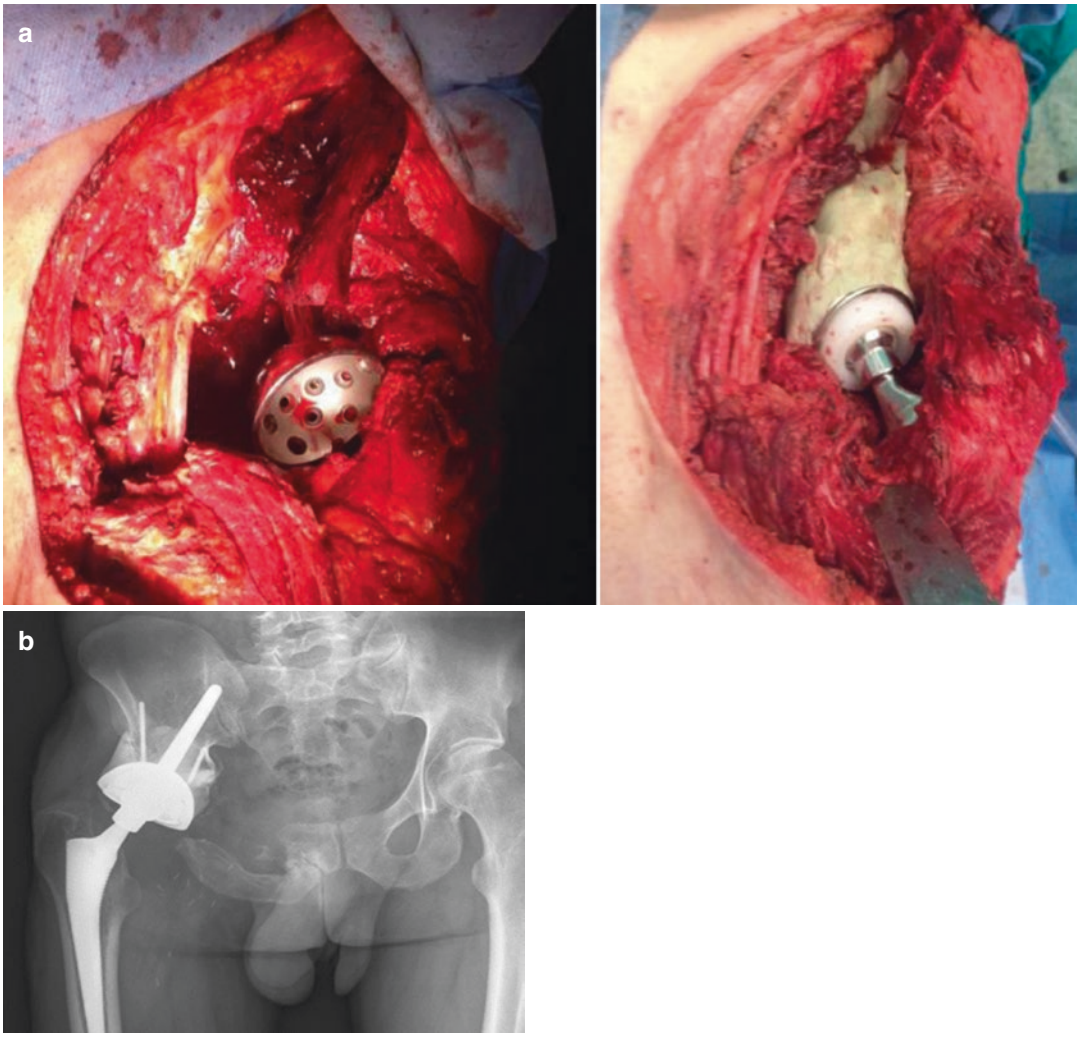

Fig. 15.4 (**a**) Intraoperative photograph, we can observe an implanted ice cream cone prosthesis with restored gap and limb length with the PMMA. Dual-mobility nonconstrained polyethylene and chrome-cobalt head were implanted to restore the joint. (**b**) AP radiographs that show the reconstruction

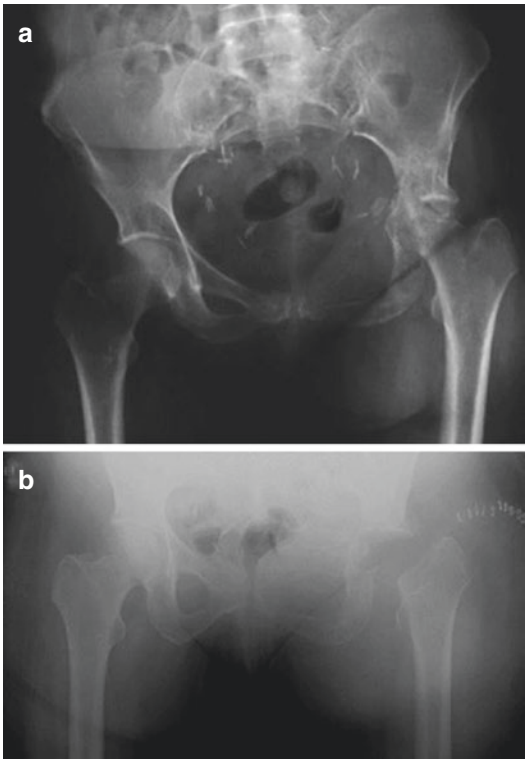

Fig. 15.5 (**a**) Plain X-rays show an acetabular protrusion of a 59-year-old female affected by bladder carcinoma and multiples metastases. She has severe left hip pain. She cannot bear any weight, and she has a pathologic fracture involving a posterior column and pubic osteolysis but poor medical condition and previous radiation therapy. Therefore, the surgical indication to relieve the pain was a resection arthroplasty. (**b**) Plain X-Rays show a resection arthroplasty of the left hip

In cases where there are no further reconstruction options available or in those patients in whom the surgical risk is high, we have to consider a resection arthroplasty (Fig. 15.5) [23]. Hindquarter amputation is the last measure reserved for cases of tumor fungating through skin, non-suppressive deep infections, or intractable pain.

15.3 Summary

We hope with time, these complicated reconstructions will be addressed more easily with more standard and predictable implant reconstruction techniques. As these resections and reconstructions involve risk of complications and blood loss, it is important to determine preoperatively if the benefits recompense the risks.

Although the reconstruction of defects in the lower limb following the resection of primary bone tumors has proved successful, the search for the optimal implant to reconstruct pelvic defects continues.

Resection of pelvic tumors is a technically demanding procedure and reconstruction demands the all-embracing use of modern surgical techniques and orthopedic implant technology [24, 25]. Several reconstructive techniques have been recommended with modest functional results and a high incidence of complications.

We must not underestimate the worth of a multidisciplinary team composed of experienced specialists devoted to the common goals of providing the best comprehensive treatment now available and helping to progress these treatment modalities in the future.

References

1. Capanna R, Campanacci DA. The treatment of metastases in the appendicular skeleton. J Bone Joint Surg Br. 2001;83(4):471–81.
2. Chow E, Harris K, Fan G, et al. Palliative radiotherapy trials for bone metastases: a systematic review. J Clin Oncol. 2007;25:1423–36.
3. Ellsworth SG, Alcorn SR, Hales RK, McNutt TR, DeWeese TL, Smith TJ. Patterns of care among patients receiving radiation therapy for bone metastases at a large academic institution. Int J Radiat Oncol Biol Phys. 2014;89(5):1100–5.
4. Rosenthal D, Callstrom MR. Critical review and state of the art in interventional oncology: benign and metastatic disease involving bone. Radiology. 2012; 262(3):765–80.
5. Lane MD, Le HB, Lee S, Young C, Heran MK, Badii M, Clarkson PW, Munk PL. Combination radiofrequency ablation and cementoplasty for palliative treatment of painful neoplastic bone metastasis: experience with 53 treated lesions in 36 patients. Skelet Radiol. 2011;40(1):25–32.
6. Toyota N, Naito A, Kakizawa H, Hieda M, Hirai N, Tachikake T, Kimura T, Fukuda H, Ito K. Radiofrequency ablation therapy combined with cementoplasty for painful bone metastases: initial experience. Cardiovasc Intervent Radiol. 2005;28(5):578–83.
7. Carrafiello G, Laganà D, Mangini M, Fontana F, Dionigi G, Boni L, Rovera F, Cuffari S, Fugazzola C.

Microwave tumors ablation: principles, clinical applications and review of preliminary experiences. Int J Surg. 2008;6(Suppl 1):S65–9.
8. Pusceddu C, Sotgia B, Fele RM, Ballicu N, Melis L. Combined microwave ablation and cementoplasty in patients with painful bone metastases at high risk of fracture. Cardiovasc Intervent Radiol. 2016; 39(1):74–80.
9. Maccauro G, Liuzza F, Scaramuzzo L, Milani A, Muratori F, Rossi B, Waide V, Logroscino G, Logroscino CA, Maffulli N. Percutaneous acetabuloplasty for metastatic acetabular lesions. BMC Musculoskelet Disord. 2008;9:66.
10. Castaneda Rodriguez WR, Callstrom MR. Effective pain palliation and prevention of fracture for axial-loading skeletal metastases using combined cryoablation and cementoplasty. Tech Vasc Interv Radiol. 2011;14(3):160–9.
11. Wunder JS, Ferguson PC, Griffin AM, Pressman A, Bell RS. Acetabular metastases: planning for reconstruction and review of results. Clin Orthop Relat Res. 2003;415S:187–97.
12. Enneking WF. The anatomic considerations in tumor surgery: pelvis. In: Enneking WF, editor. Musculoskeletal tumor surgery, vol. 2. New York: Churchill Livingstone; 1983. p. 483–529.
13. Muller D, Capanna R. The surgical treatment of pelvic bone metastases. Adv Orthop. 2015;75:1–10.
14. Piccioli A, Spinelli MS, Forsberg JA, Wedin R, Healey JH, Ippolito V, Daolio PA, Ruggieri P, Maccauro G, Gasbarrini A, Biagini R, Piana R, Fazioli F, Luzzati A, Di Martino A, Nicolosi F, Camnasio F, Rosa MA, Campanacci DA, Denaro V, Capanna R. How do we estimate survival? External validation of a tool for survival estimation in patients with metastatic bone disease-decision analysis and comparison of three international patient populations. BMC Cancer. 2015;15:424.
15. Forsberg JA, Eberhardt J, Boland PJ, Wedin R, Healey JH. Estimating survival in patients with operable skeletal metastases: an application of a Bayesian belief network. El-Deiry WS, ed. PLoS One. 2011;6(5):e19956.
16. Harrington KD. The management of acetabular insufficiency secondary to metastatic malignant disease. J Bone Joint Surg Am. 1981;4:653–64.
17. Issack PS, Kotwal SY, Lane JM. Management of metastatic bone disease of the acetabulum. J Am Acad Orthop Surg. 2013;21(11):685–95.
18. Wood TJ, Racano A, Yeung H, Farrokhyar F, Ghert M, Deheshi BM. Surgical management of bone metastases: quality of evidence and systematic review. Ann Surg Oncol. 2014;21(13):4081–9.
19. Ruggieri P, Mavrogenis AF, Angelini A, Mercuri M. Metastases of the pelvis: does resection improve survival? Orthopedics. 2011;34(7):e236–44.
20. Harrington KD. The management of acetabular insufficiency secondary to metastatic malignant disease. J Bone Joint Surg Am. 1981;63A:653–64.
21. Harrington KD. The management of acetabular insufficiency secondary to metastatic malignant disease. J Bone Joint Surg Am. 1981;63(4):653–64.
22. Sagozis P, Wedin R, Brosjö O, Bauer H. Reconstruction of metastatic acetabular defectsusing a modified Harrington procedure: good outcome after surgical treatment of 70 patients. Acta Orthop. 2015;86(6): 690–4.
23. Quinn RH. Metastatic disease to the hip and pelvis: surgical management. Tech Orthop. 2007;22(2).
24. Barrientos-Ruiz I, Ortiz-Cruz EJ, Peleteiro-Pensado M. Reconstruction after hemipelvectomy with the ice-cream cone prosthesis: what are the short-term clinical results? Clin Orthop Relat Res. 2017;475: 735–41.
25. Barrientos-Ruiz I, Ortiz-Cruz EJ, Peleteiro-Pensado M. Erratum to: reconstruction after hemipelvectomy with the ice-cream cone prosthesis: what are the short-term clinical results. Clin Orthop Relat Res. 2017;475:924.