

SELNET clinical practice guidelines for bone sarcoma

JY Blay^{a,*}, E. Palmerini^b, J. Bollard^a, S. Aguiar, Jr^c, M. Angel^d, B. Araya^e, R. Badilla^e, D. Bernabeu^f, F. Campos^c, Caro-Sánchez CHS^g, A. Carvajal Montoya^e, S. Casavilca-Zambrano^h, Castro-Oliden V^h, M. Chacón^d, MA Clara-Altamirano^g, P. Colliniⁱ, R. Correa Genoroso^j, FD Costa^c, M. Cuellar^g, AP dei Tos^k, HR Dominguez Malagon^g, DM Donati^b, A. Dufresne^a, M. Eriksson^l, M. Farias-Loza^h, AM Frezzaⁱ, T. Frisoni^b, DY Garcia-Ortega^g, H. Gerderblom^m, F. Gouin^a, MC Gómez-Mateoⁿ, A. Gronchiⁱ, J. Haro^h, N. Hindi^o, L. Huanca^h, N. Jimenez^p, M. Karanian^a, B. Kasper^q, A. Lopes^c, BB Lopes Davidⁱ, A. Lopez-Pousa^r, G. Lutter^d, RG Maki^s, H. Martinez-Said^t, JL Martinez-Tlahuel^g, CA Mello^c, JM Morales Pérez^t, DS Moura^u, SA Nakagawa^c, AG Nascimento^c, EJ Ortiz-Cruz^v, S. Patel^w, Y. Pfluger^d, S. Provenzanoⁱ, A. Righi^b, A. Rodriguez^d, TG Santos^c, K. Scotlandi^b, Silva MLG^c, T. Soulé^d, S. Stacchiottiⁱ, CM Valverde^x, F. Waisberg^d, E. Zamora Estrada^e, J. Martin-Broto^o

^a Léon Bérard Center, 28 rue Laennec 69373 Lyon Cedex 08, France

^b IRCCS Istituto Ortopedico Rizzoli, University of Bologna, Via Pupilli, 1, 40136, Bologna, Italy

^c A.C. Camargo Cancer Center, Rua prof Antonio Prudente, 211 - Liberdade, São Paulo 01509-010, Brazil

^d Instituto Alexander Fleming, Av. Cramer 1180. CP, C1426ANZ Buenos Aires, Argentina

^e Hospital Dr. R. A. Calderón Guardia, 7-9 Av, 15-17 St, Aranjuez, San José, Costa Rica

^f Hospital Universitario La Paz, Paseo de la Castellana, 261, 28046 Madrid, Spain

^g Instituto Nacional de Cancerología, Torre Nueva de Hospitalización, primer piso. Av. San Fernando 86, Colonia Niño Jesús. CP, 14080 Tlalpan Mexico

^h Instituto Nacional de Enfermedades Neoplásicas, Av. Angamos Este 2520, Lima, Peru

ⁱ Fondazione IRCCS Istituto Nazionale dei Tumori, Via Giacomo Venezian, 1, 20133 Milano, Italy

^j Hospital Clínico Universitario Virgen de la Victoria, Campus Universitario de Teatinos s/n, 29010, Malaga, Spain

^k Treviso General Hospital Treviso, University of Padua, Padova, Italy

^l Skane University Hospital and Lund University, Lund, Sweden

^m Leiden University Medical Center, Leiden, The Netherlands

ⁿ Hospital Universitario Miguel Servet, Paseo Isabel la Católica, 1-3, 50009 Zaragoza, Spain

^o Research Health Institute Fundación Jiménez Díaz (IIS/FJD), 28015 Madrid, Spain; Hospital Fundación Jiménez Díaz University Hospital, 28040 Madrid, Spain;

General de Villalba University Hospital, 28400 Madrid, Spain

^p Hospital San Vicente de Paúl, Avenue 16, streets 10 and 14, Heredia, Costa Rica

^q University of Heidelberg, Mannheim Cancer Center, Theodor-Kutzer-Ufer 1-3, 68167 Mannheim, Germany

^r Hospital de la Santa Creu i Sant Pau, Carrer de Sant Quintí, 89, 08041 Barcelona, Spain

^s University of Pennsylvania, Abramson Cancer Center, 3400 Civic Center Boulevard, Philadelphia, PA 19104 USA

^t Centro Oncológico Integral, Hospital Medica Sur, Planta Baja Torre III - Cons. 305, Col. Toriello Guerra, Deleg. Tlalpan. C.P., 14050, Mexico, D.F

^u Hospital Universitario Virgen del Rocío, Av Manuel Siurot s/n, 41013 Sevilla, Spain

^v Hospital Universitario La Paz, MD Anderson Cancer Center, Calle de Arturo Soria, 270, 28033 Madrid, Spain

^w UT MD Anderson Cancer Center, Houston, TX, USA

^x Vall d'Hebrón University Hospital, Passeig de la Vall d'Hebrón, 119, 08035 Barcelona, Spain

ARTICLE INFO

Keywords:

Bone sarcoma
Clinical guidelines
Latin-America context

ABSTRACT

Bone sarcoma are infrequent diseases, representing < 0.2% of all adult neoplasms. A multidisciplinary management within reference centers for sarcoma, with discussion of the diagnostic and therapeutic strategies within an expert multidisciplinary tumour board, is essential for these patients, given its heterogeneity and low frequency. This approach leads to an improvement in patient's outcome, as demonstrated in several studies. The Sarcoma European Latin-American Network (SELNET), aims to improve clinical outcome in sarcoma care, with a

* Correspondence to: Centre Léon Bérard, 28 rue Laennec Cedex 08, 69373 Lyon, France.

E-mail address: jean-yves.blay@lyon.unicancer.fr (J. Blay).

<https://doi.org/10.1016/j.critrevonc.2022.103685>

Received 9 March 2022; Received in revised form 14 April 2022; Accepted 14 April 2022

Available online 21 April 2022

1040-8428/© 2022 The Authors. Published by Elsevier B.V. This is an open access article under the CC BY license (<http://creativecommons.org/licenses/by/4.0/>).

special focus in Latin-American countries. These Clinical Practice Guidelines (CPG) have been developed and agreed by a multidisciplinary expert group (including medical and radiation oncologist, surgical oncologist, orthopaedic surgeons, radiologist, pathologist, molecular biologist and representatives of patients advocacy groups) of the SELNET consortium, and are conceived to provide the standard approach to diagnosis, treatment and follow-up of bone sarcoma patients in the Latin-American context.

1. Introduction and epidemiology

Bone sarcomas constitute a heterogeneous group of rare neoplasms, representing less than 0.2% of all malignant tumours in Europe (Stiller et al., 2013), and approximately 10% of all sarcomas. The estimated incidence in Europe is of 0.2–0.3 new cases/100.000 inhabitants/year (Berner et al., 2015; Valery et al., 2015; Whelan et al., 2012), with a similar incidence in other regions (Mirabello et al., 2009; Moreno et al., 2017). Osteosarcoma and Ewing sarcoma (ES) have a higher incidence in adolescents and young adults, with male predominance (Jawad et al., 2009; Mirabello et al., 2009). In contrast, chordoma and chondrosarcoma are more frequent in older population (Valery et al., 2015; Yu et al., 2016).

1.1. General statements

- Management of bone sarcoma should be carried out within multidisciplinary reference centres for sarcoma or expert networks [III, A]. Multidisciplinary tumour boards (MDTB) should include at least the following specialties: medical oncology, paediatrics (if paediatric patients are discussed), radiology, surgery, pathology and radiation oncology.
- A MDTB cannot be defined only by the volume of patients followed, but also by the periodicity of meeting (weekly MDTB is recommended), its contribution to clinical trials and scientific production, its participation in national or international guidelines. These MDTB ideally should be periodically audited to ensure quality.
- All diagnostic procedures and therapeutic decisions should be discussed within a MDTB (Andreou et al., 2011; Blay et al., 2017; Mankin et al., 1982).
- The diagnosis procedures are identical for all bone sarcomas [I, A] (Fig. 1).
- Discussion of fertility preservation strategies is strongly advised in younger patients when systemic treatment is considered for localized

disease, in patients with osteosarcoma and Ewing sarcoma (Casali et al., 2018).

- Several reports indicate better clinical results and better cost-effectiveness if sarcoma or presumptive sarcoma patients are managed within MDTB [III, A] (Blay et al., 2019).

1.2. Diagnosis and pathology/molecular biology

The recommended imaging test upon suspicion of bone tumour is X-ray of affected extremities and MRI of the entire compartment and nearby joints; a CT scan should be performed in case of a suspected bone sarcoma of the trunk and head and neck [III, A] (Meyer et al., 2008). Preoperative biopsy is strongly recommended. Core-needle is preferred to incisional biopsy, but both are valid when performed by an expert team [III, A] (Andreou et al., 2011; Blay et al., 2017; Casali et al., 2018), aiming to obtain enough material for a correct diagnosis. A fine needle aspirate is generally inadequate to make a sarcoma diagnosis, though it can be useful in confirming recurrence or metastasis. Central pathology review, with molecular characterization as appropriate according to pathologist and available resources (for example when Ewing sarcoma is suspected), is strongly recommended [III, A] (Abdul-Karim et al., 2004; Board; Casali et al., 2018).

1.3. Staging and risk assessment

The initial staging to rule out distant metastasis requires chest CT scan ± abdominal and pelvic CT scan [III, A] (Picci et al., 2001). Whole-body FDG-PET or whole-body MRI may be useful for staging purposes if available [III, A] (Barnett et al., 2020; Buchbender et al., 2012; Völker et al., 2007). As an alternative, for osteosarcoma and ES staging, bone scintigraphy is adequate, if PET-CT or whole-body MRI are not available to exclude bone involvement [III, A] (Hurley et al., 2016). Iliac bone marrow biopsy is not currently a universally accepted standard work-up in Ewing sarcoma, as the percentage of bone involvement exclusively detected by bone marrow biopsy is extremely low (< 0.5%) (Cesari et al., 2019).

Adverse prognostic factors for localized conventional osteosarcoma include: large tumour size (different cut-offs used as larger than one third of the whole diameter of bone; or 15 cm; or 150 ml in studies considering volume), tumor site (axial or proximal limbs was worse), elevated serum alkaline phosphatase (AP) or lactate dehydrogenase (LDH) and older age (older than 15 years, but also older than 40 years) (Basile et al., 2020; Bielack et al., 2002; Bramer et al., 2009; Picci et al., 1994). Another independent relevant prognostic factor is the poor histological response ($\geq 10\%$ viable tumour cells) after neoadjuvant chemotherapy (Picci et al., 1994). As expected, metastatic spread is a relevant prognostic factor in osteosarcoma.

Standard staging classification system is not widely accepted among physicians treating Ewing sarcoma (Enneking et al., 1980; Heck et al., 2006; JD and MK, 2016). A pragmatical risk-based approach to allocate different treatments in Ewing sarcoma is based on volume of primary tumour (< 200 ml vs ≥ 200 ml), localized vs metastatic disease (within this latter exclusive lung vs extrapulmonary metastasis) and good or poor histological response to induction chemotherapy ($\geq 10\%$ viable tumour cells constituted poor response) (Bacci et al., 2004, 2000; Cotterill et al., 2000; Le Deley et al., 2010; Leavey and Collier, 2008; Nesbit et al., 1990; Paulussen et al., 2008; Schuck et al., 2003; van Doorninck et al., 2010).

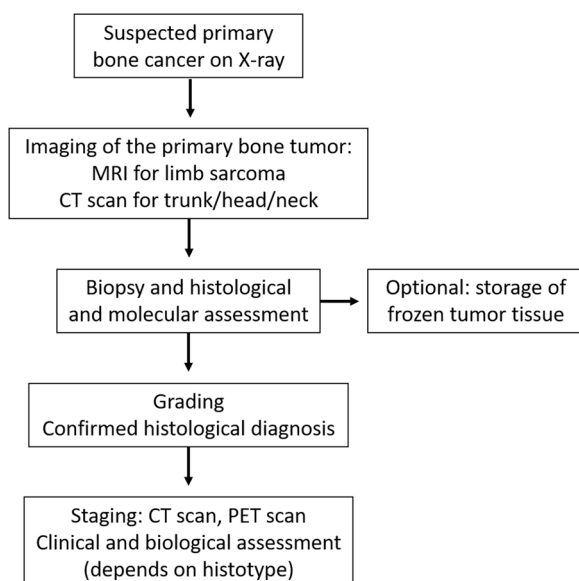


Fig. 1. General diagnostic strategy for bone sarcomas.

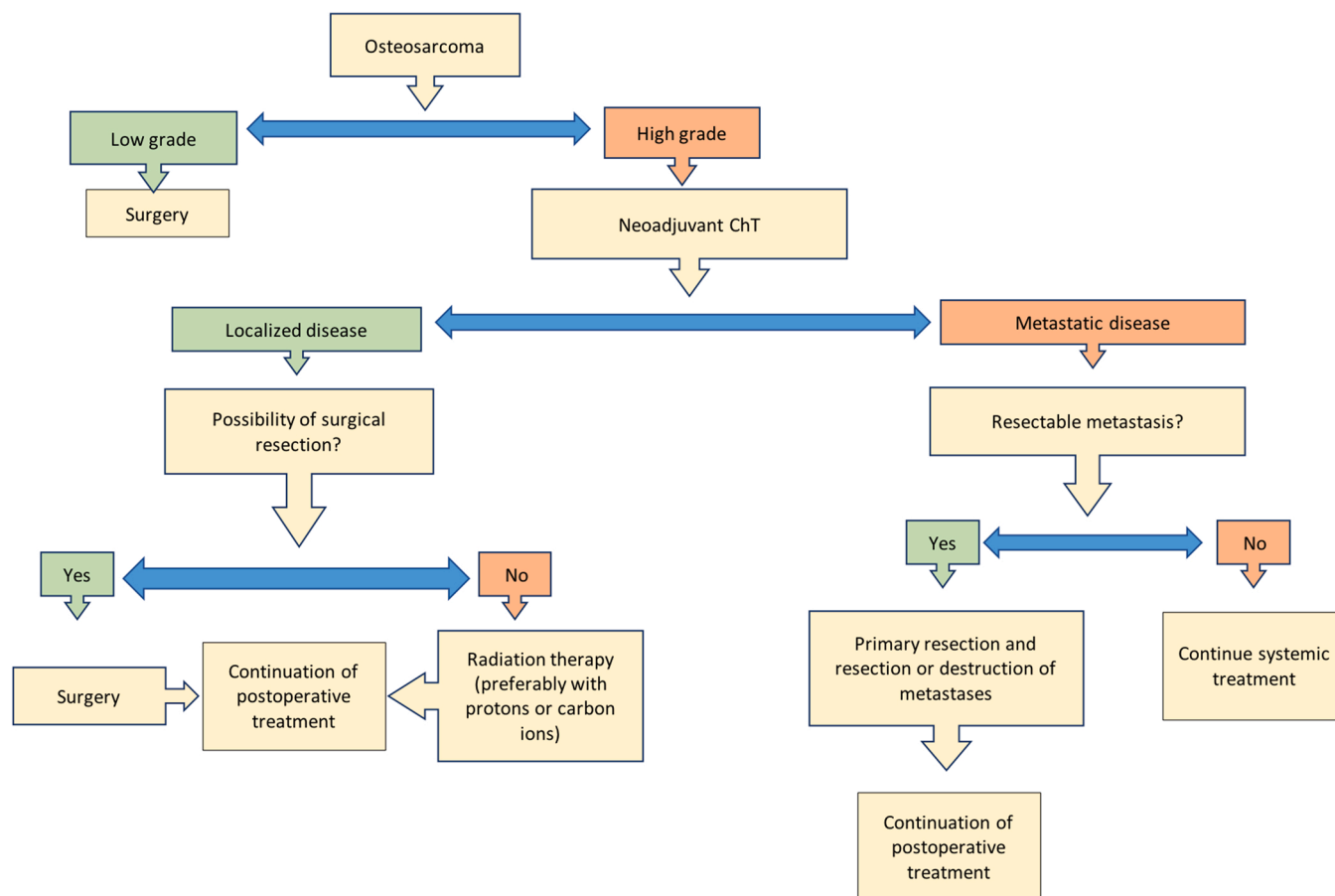


Fig. 2. Osteosarcoma treatment strategy.

1.4. Treatment (local and advanced disease) of bone sarcomas

1.4.1. Osteosarcoma (Fig. 2)

1.4.1.1. High-grade osteosarcoma. Chemotherapy (ChT) is a key component of multimodal therapy of high-grade osteosarcoma, and it is associated with an increase in disease-free survival (from 20% to >60%) and overall survival when compared with surgery alone (Bernthal et al., 2012). Treatment should be initiated as soon as possible, ideally within 15 days to 30 days following the biopsy. Restaging is recommended in case of delay. Systemic treatment should be the same in case of curative or palliative intent (in terms of intensity and dose) (Lewis et al., 2007). Neoadjuvant ChT is recommended for high grade osteosarcoma [I, A] (Bielack et al., 2002; Brammer et al., 2009; Picci et al., 1994). The MAP regimen (doxorubicin/cisplatin/high-dose methotrexate [HD-MTX]) is most frequently used in children and young adults (Bielack et al., 2015; Ferrari et al., 2005; Whelan et al., 2015; Whelan and Davis, 2018), although HD-MTX (>8 g/m²) may be difficult to manage in adults > 40 years old (Ferrari et al., 2018; Marina et al., 2016). Combinations of doxorubicin, cisplatin and ifosfamide without HD-MTX can be used as an alternative. The combination of cisplatin and doxorubicin is an option for patients older than 40 years [I, A],[40, 41, 43, 45] but the addition of HD-MTX may be feasible in adults beyond 40 year old according to individual centre expertise (Bielack et al., 2015; Ferrari et al., 2018; Marina et al., 2016; Whelan et al., 2015; Whelan and Davis, 1). Usually, two MAP cycles are recommended as neoadjuvant treatment before surgery of primary tumour. It is relevant to synchronize the surgery after recovery of blood count (usually 3–4 weeks after the last cycle) and to synchronize the starting of adjuvant chemotherapy after recovery of surgical wound (usually after 2–3 weeks) (Bielack et al.,

2004; Carrle and Bielack, 2006; Ferrari et al., 2005; Goorin et al., 2003; Lewis et al., 2007; Marina et al., 2016; Meyers et al., 2008; Whelan et al., 2015; Whelan and Davis, 1). Whenever possible, patients should receive chemotherapy within the context of clinical trials. In order to control cardiac and renal side effects, LVEF determination and 24 h creatinine clearance analysis should be performed prior to systemic ChT prescription (Casali et al., 2018). ECG/QTc measurements could be performed during therapy. Wide surgical resection (with negative margins) is the standard treatment after neoadjuvant treatment [I, A] with limb salvage whenever possible. If wide margins or adequate function are not achievable, even after bone and soft tissue reconstruction, amputation should be considered (Rose, 2020). Preoperative core-needle biopsy track should be included in the surgical resection [III, A] (Casali et al., 2018). Surgical margins should be reported according to Enneking system adopted by MSTs (Musculoskeletal Tumour Society) or R0/R1 systems, and mentioned in the pathology report. The percentage of residual tumour cells after neoadjuvant ChT is a strong prognostic factor and should be mentioned in the report [I, A]. Re-resection should be considered in case of unplanned/inadequate surgery [IV, B]. If R1 resection was performed without option for reoperation, adjuvant RT could be considered after discussion in the MDTB [V, B]. Post-operative adjuvant chemotherapy should be administered using the same drugs, prescribed in neoadjuvant setting, for at least two further cycles [I, A]. For patients with tumours with poor response after neoadjuvant ChT (HUVOS 1, 2), there is no consensus regarding changing the chemotherapy regimen in the adjuvant setting [I, C] (Lewis et al., 2007; Marina et al., 2016). If available, the addition of muramyl tripeptide to post-operative ChT may improve survival for patients < 30 year old with completely resected localized osteosarcoma [II, B] (Meyers et al., 2008). Macroscopic complete remission should be the aim of the treatment in

both metastatic and non-metastatic osteosarcoma [III, B] (Lewis et al., 2007). For high-grade metastatic osteosarcoma, primary tumour resection and resection or destruction (e.g. stereotactic radiotherapy) of metastases are recommended (Ferrari et al., 2003). Osteosarcoma is relatively radioresistant and, in cases where surgery is not feasible, carbon ion or proton beam therapy should be discussed [IV, A] and preferred, if available (Leroy et al., 2016). If treatment strategies are not available in the country, a recommendation to perform such treatments in foreign centres could be considered [II, B]. When this is not possible, high-dose conventional RT can be offered [III, B].

1.4.1.2. Low-grade osteosarcoma. Low-grade osteosarcoma includes central low-grade osteosarcoma, parosteal osteosarcoma and periosteal osteosarcoma. Immunohistochemistry (IHC) and/or fluorescence in situ hybridization (FISH) are useful to confirm MDM2 amplification in the context of parosteal and central low-grade osteosarcoma. For low-grade osteosarcoma, wide surgical resection without systemic treatment is the standard approach [III, A]. Marginal resection is acceptable in selected cases [III, B] (Cesari et al., 2011; Grimer et al., 2005; Laitinen et al., 2015).

1.4.1.3. Osteosarcoma of the jaw. The usual treatment for high-grade osteosarcomas of the jaw includes neo-adjuvant or adjuvant ChT and wide resection [III, A]. High-grade craniofacial osteosarcoma could be treated in the same way as high-grade osteosarcomas at other locations [III, B]. However, some authors defend different approaches, as to initiate with surgery, since the main risk in this location is related to local recurrence (Ferrari et al., 2017). There is not a clear reason to avoid chemotherapy in the context of high-grade craniofacial osteosarcoma, given the high-risk nature of any recurrence, local or distant. For a better assessment, PET-TC can offer valuable predictive information in osteosarcoma of this location (Frezza et al., 2014). High-dose RT can be used when complete (R0) surgery is not feasible [IV, B], following the end of chemotherapy (Casali et al., 2018).

1.4.1.4. Treatment of recurrent osteosarcoma. The treatment of recurrent osteosarcomas should take into account the timing of recurrence and the number and location of the metastases (Lewis et al., 2007). Number and bilaterality of lung metastases, metastatic pattern and disease-free interval (> 2 years) are known prognostic factors for recurrent osteosarcoma. For limited number of lung metastases, complete surgical resection should be attempted, with stereotactic RT as alternative option for patients unfit for surgery (Bielack et al., 2004; Carrle and Bielack, 2006; Lewis et al., 2007; Yu et al., 2017). The role of second-line therapy for recurrent osteosarcoma is not well defined but options include ifosfamide or cyclophosphamide, with etoposide and/or carboplatin; high-dose ifosfamide; gemcitabine plus docetaxel [III, A] (Berger et al., 2009; Fagioli et al., 2002; Gentet et al., 1997; Palmerini et al., 2016, 2020b). Several oral antiangiogenic agents have shown activity, including regorafenib [II, B] and sorafenib [III, B] (Duffaud, Florence et al., 2019; Grignani et al., 2015).

1.4.2. Ewing sarcoma

The general strategy for the treatment of localized ES includes neo-adjuvant ChT, then treatment of the primary tumour with wide surgical resection and/or RT, followed by adjuvant ChT [I, A]. In case of metastatic disease, in addition to systemic therapy, an attempt to treat all sites of metastases with radiotherapy and/or surgery should be attempted [III, A].

1.4.2.1. Molecular diagnostic and staging. All ES are high-grade tumours and are defined by TET-ETS fusions usually involving the *EWSR1* gene on chromosome 22, in a reciprocal translocation t(11;22)(q24;q12). Recently, expert pathologists incorporated a new chapter identified as undifferentiated small round cell sarcomas of bone and soft tissue, in the

new WHO sarcomas classification (Board, n.d.). This new section encompasses three different subsets, apart from Ewing sarcoma, namely: *EWSR1* gene fusion with non-ETS family gene round-cell sarcomas, *CIC* rearranged sarcomas and *BCOR* rearranged sarcomas (Antonescu et al., 2017; Bridge et al., 2019; Kao et al., 2018). Most ES tumours or Ewing-like tumours can be recognized or suspected with classical haematoxylin and eosin stain and IHC, but molecular confirmation is strongly recommended to confirm diagnosis [III, A] and to perform differential diagnosis with other previously mentioned small round cell sarcomas (Antonescu et al., 2017; Brennan et al., 2020; Gaspar et al., 2015; Grier et al., 2003; Machado et al., 2009; Sorensen et al., 1994; Zoubek et al., 1994).

1.4.2.2. Treatment. Neoadjuvant chemotherapy is recommended for all Ewing sarcomas [II, A]. Chemotherapy is based on five- to six-drug combinations including doxorubicin, cyclophosphamide, ifosfamide, vincristine, dactinomycin and etoposide (Gaspar et al., 2015; Grier et al., 2003; Nesbit et al., 1990; Paulussen et al., 2008; Schuck et al., 2003; van Doorninck et al., 2010). Combination of alternating VDC-IE, is more active than VIDE/VAI according to the EuroEwing2012 trial [II, A] and is the standard recommended regimen (Brennan et al., 2020). Current trials use 6–9 cycles of initial combination ChT as induction, followed by local therapy with another 5–8 cycles of ChT, usually at 2/3-week intervals [II, A]. Short intervals (every 2 weeks) have demonstrated to be significantly better in terms of event-free survival than standard 3-week interval for alternating VDC/IE regimen. This difference did not reach a significant level in patients 18 years of age [II, B] (Womer et al., 2012). High dose chemotherapy with busulfan and melphalan (BuMel) and autologous bone marrow rescue improved survival over conventional adjuvant chemotherapy alone as consolidation in patients with large > 200 ml tumours or poor response to neoadjuvant chemotherapy [II, A]. This should be considered in localized high-risk patients if feasible (Ferrari et al., 2011; Whelan et al., 2018). Wide surgical resection is recommended for local control [II, A]. In case of bone ES, surgeons should consider the initial volume for bone resection [III, B]. Radiotherapy (45–70 Gy, depending on location and intent) is recommended after surgery, in particular when complete excision is not possible, margins are positive, the initial volume of soft-part component cannot be completely resected or in cases with pathological poor response [II, A]. RT may be given to the primary tumour site preoperatively or postoperatively and is recommended as definitive local treatment when surgical excision to obtain adequate margins is not possible or considered as too morbid [II, A] (Schuck et al., 2003). The treatment principles for extraskeletal ES are the same as for skeletal ES. Cases with metastatic disease at diagnosis are treated in the same way as localized cases, attempting to treat all sites of metastases with radiotherapy and/or surgery [III, A] (Haeusler et al., 2010). Whole-lung irradiation is an option for patients with clinically evident lung metastases as prophylactic use [III, C] (Bölling et al., 2008). For patients with recurrent ES, an extended time to relapse is a favourable prognostic factor [III, B] (Stahl et al., 2011). There are no standard ChT regimens for recurrent disease and options include cyclophosphamide plus topotecan, ifosfamide plus etoposide, high-dose ifosfamide, irinotecan with temozolomide or gemcitabine plus docetaxel (Ferrari et al., 2009; Fox et al., 2012; Saylor et al., 2001; Wagner et al., 2004). Interestingly, information derived from the rEECur trial (EudraCT 2014-000259-99, a multi-arm phase II/III drop-a-loser randomized trial) showed that gemcitabine and docetaxel was less active than the remaining high-dose ifosfamide, irinotecan plus temozolomide, or cyclophosphamide plus topotecan after the first interim analysis (McCabe et al., 2019). Additionally, in a second analysis, irinotecan plus temozolomide was significantly less active than the remaining arms (McCabe et al., 2020). Thus, high-dose ifosfamide and cyclophosphamide plus topotecan have shown to be the most active schemes in second lines of progressing metastatic Ewing sarcoma. The study is still ongoing, testing new arms. For high-dose ifosfamide, 2

schemes were used: administration over 5 days q 3 weeks (12–15 g/m²) or 14 days q 4 weeks in continuous infusion by elastomeric pumps (14 g/m²) [III, A]. A randomized clinical trial testing these options is ongoing (NCT01864109).

Currently, there are no clear data to support a different first-line treatment for *CIC*- or *BCOR*-rearranged sarcomas than that used for classical ES (Palmerini et al., 2020a).

1.4.3. High grade spindle/pleomorphic sarcomas of the bone

Pleomorphic sarcomas of the bone are found in a similar age group to chondrosarcoma patients with an osteosarcoma-like skeletal distribution (Pakos et al., 2011). Any diagnosis of undifferentiated high grade bone sarcomas on a core biopsy should be integrated within the clinical-radiological context, in order to rule out other entities with undifferentiated components. Treatment strategy is similar to that of osteosarcoma with wide surgical margins including any soft tissue component in combination with ChT. This group of tumours is less chemo-sensitive. ChT regimens based on doxorubicin, ifosfamide, and/or platinum are generally recommended [IV, B] (Bramwell et al., 1999). The role of HDMTX in these tumours remains unclear. The added value of platinum compounds in this context is also unknown [IV, C] (Nooij et al., 2005). RT may be considered for inoperable lesions. Adjuvant RT may be considered for lesions which have been operated (R1) or in case of resected local relapse [IV, C].

1.4.4. Chondrosarcoma

Most chondrosarcoma are grade 1: when located on the limbs, the term atypical cartilaginous tumour is most often used vs grade 1 chondrosarcoma for tumours at other locations (trunk and head and neck) (Bovee et al., 2020). Assessing the grade in chondrosarcoma can be difficult, and requires an adequate radiological-pathological correlation (D et al., 2009; Ferrer-Santacreu et al., 2016; Gelderblom et al., 2008; Whelan and Davis, 1). Pain at a cartilaginous lesion may be a sign to suspect malignancy (Ferrer-Santacreu et al., 2016). *IDH* mutation analysis may be considered as an option when a chondrosarcoma is suggested by radiological imaging [III, C].

1.4.4.1. Treatment. Atypical cartilaginous tumours/grade 1 chondrosarcoma of long bones can be managed with intralesional extended curettage (large cortical window, high-speed burr) with or without local adjuvant therapy, such as phenol, cryotherapy and reconstruction with cement or bone graft [IV, A] (Chen et al., 2017; Leerapun et al., 2007). Pelvic grade 1 chondrosarcomas should be completely resected, with en bloc resection, or if this is not feasible, with intralesional resection [IV, A]. Grade 2 and 3 chondrosarcoma and all chondrosarcomas, irrespective of grade, if are located in pelvis or axial skeleton should be surgically excised with wide margins [IV, A] (Fiorenza et al., 2002). In pelvic chondrosarcoma, every effort should be made to offer limb-sparing en bloc resection (internal hemipelvectomy) when feasible. In inoperable, locally advanced high-grade chondrosarcomas, RT with proton beam or carbon ion therapy can be proposed [III, A] (Noël et al., 2004). Dedifferentiated chondrosarcoma is a very aggressive entity and can be treated as a high-grade bone sarcoma, with chemotherapy adapted to patient age. When wide margins are not foreseen with limb salvage, amputation should be considered in the high-grade chondrosarcoma context [IV, B] (Dickey et al., 2004; Grimer et al., 2007). ChT options include cisplatin, doxorubicin, ifosfamide, or gemcitabine plus docetaxel [IV, C] (Fox et al., 2012; Italiano et al., 2013). One trial reported activity of regorafenib [II, B] (F. Duffaud et al., 2019). Mesenchymal chondrosarcoma should be considered for adjuvant or neoadjuvant ChT with an Ewing-type regimen [IV, B] (Dantonello et al., 2008; Frezza et al., 2015).

1.4.5. Giant cell tumour of bone

Giant cell tumour (GCT) of bone is a benign, locally aggressive

tumour with *H3F3A* gene mutations in most of the cases and a low probability of metastatic spread (Amelio et al., 2016; Behjati et al., 2013; Liede et al., 2014). GCT of bone may suffer malignant transformation and can metastasize even in the absence of malignant transformation.

1.4.5.1. Treatment. Treatment options include wide surgical resection and intralesional extended curettage with adjuvant therapy, such as phenol, cement and cryotherapy in carefully selected cases [IV, A] (van der Heijden et al., 2020). Some authors advocate that preferential treatment is intralesional extended curettage and high-speed drilling with local adjuvants including phenol, alcohol, or liquid nitrogen, and cavity filling with bone graft and/or polymethylmethacrylate (PMMA) [IV, A].

Denosumab should be considered for unresectable or metastatic GCT [III, A]. The role of neo-adjuvant denosumab in operable GCT of bone is limited to selected cases in which diffuse reactive bone formation and peripheral ossification can render an easier surgical procedure, for example those tumours with a large soft tissue component [III, B] (Rutkowski et al., 2018; van der Heijden et al., 2017). Side effects of denosumab, including osteonecrosis of the jaw and atypical fractures, should be monitored. Co-administration of calcium and vitamin D is recommended during denosumab administration. The duration of treatment is connected to the risk of osteonecrosis of the jaw (ONJ) [II, A]. It is not yet defined the most convenient schedule, or duration for denosumab treatment in the context of unresectable GCT. The decision on the duration of treatment should take into account that ONJ risk increases over time in a dose-dependent manner (Chawla et al., 2019). The role for RT is limited due to the risk of malignant transformation [IV, B], while denosumab does not seem to increase malignancy in GCT of bone (Palmerini et al., 2021; Shi et al., 2013).

1.4.6. Chordoma

This entity is an exceedingly rare bone tumour with notochordal differentiation. IHC positivity for brachyury is strongly recommended to confirm the diagnosis of conventional chordoma (Vujovic et al., 2006). Dedifferentiated chordomas are more aggressive, accounting for less than 5% of all cases, and brachyury expression is usually lost in its high-grade component. Poorly-differentiated paediatric chordoma have an aggressive behaviour and are characterized by brachyury positivity and loss of SMARCB1.

1.4.6.1. Treatment. Primary tumour treatment depends on tumour location and requires a MDTB (Stacchiotti et al., 2015). *En bloc* R0 resection is the standard treatment, when feasible [IV, A]. Surgery is the first choice for sacral tumours located below the level of S4 [III, A]. Alternative approaches may be considered for tumours originating above S3 (sacral spinal nerve 3), due to surgery-associated neurological sequelae [III, A] (Stacchiotti et al., 2015). Indications for definitive RT include unresectable disease, inoperable patients and neurological impairment not acceptable for the patient [IV, A] (DeLaney et al., 2014; Schulz-Ertner et al., 2007). For skull base and upper cervical tract chordoma, R1 surgery plus high-dose RT (74 GyE in conventional fractionation [1.8–2 GyE] for photon and proton therapy) is the treatment of choice [II, B] (Stacchiotti et al., 2015). The dose of RT to deliver in case of R1 resection or inoperable disease are debated: > 74 GyE if case of R1, > 78 GyE in case of R2 or inoperable cases [II, B]. The choice of treatment for local relapse can include surgery and/or RT and/or systemic treatment [II, B] (Stacchiotti et al., 2017). Dose escalation with proton therapy (EQD2 ~70 GyRBE), carbon ion therapy (EQD2 ~105 GyRBE) or photon-based stereotactic body radiation therapy (SBRT) (EQD2 ~150 GyRBE) may be used in case of high risk of morbidity after oncologic resection or medically inoperable patients. Dose constraints and CTV expansion may differ between techniques. There is no standard medical treatment for advanced chordoma. Options which can be

Table 1
Levels of evidence.

LEVES OF EVIDENCE	DEFINITION
I	Evidence from meta-analyses (based on well conducted clinical trials) or at least one large randomized controlled trial with low potential for bias)
II	Small randomised trial or large randomized trials/ meta-analyses with suspicion of bias or heterogeneity
III	Prospective cohort studies
IV	Case-control or retrospective cohort studies
V	Case reports, expert opinions, studies without control group
GRADES OF RECOMMENDATION	
A	Strong evidence for efficacy and meaningful clinical benefit: strongly recommended.
B	Strong or moderate evidence for efficacy but restricted clinical benefit: generally recommended
C	Inadequate evidence for efficacy or clinical benefit not exceeding risks: optional
D	Moderate evidence against efficacy or poor outcome: generally not recommended
E	Strong evidence against efficacy or poor outcome: never recommended or contraindicated

discussed depending on the clinical presentation and quality of life, include imatinib, sorafenib, and epidermal growth factor receptor inhibitors based on limited clinical evidences [III, C] (Bompas et al., 2015; Lebellec et al., 2017; Stacchiotti et al., 2013, 2012).

1.4.7. Follow-up, long-term implications and survivorship

Follow-up of high-grade bone tumours should include clinical and radiological assessments. Physical examination requires to focus on primary tumour site as well as any potential long-term side effect due to different treatments. Imaging tests for local tumour bed should include simple X-ray complemented by other techniques as MRI, CT scan or even ultrasounds. Artifacts from metallic implants makes difficult some interpretations and could require specific MRI sequences or optimization of CT protocol. A recommended follow-up policy after treatment completion is different between low-grade and high-grade bone sarcoma. For high grade tumours, follow-up every 3–4 months for the first 2–3 years, then every 6 months up to fifth year and then annually up to tenth year are recommended. For low-grade tumours, visits every 6 months for 2–5 years and annually thereafter are recommended. In ES, bone scintigraphy can be used occasionally in addition to X-ray for a more complete bone assessment; PET/CT or whole-body MRI are other potential options. Investigations for late effects should be pursued for a long-term (more than 10 years) after treatment cessation (LVEF every 2 years for patients who received doxorubicin, creatinine level assessment on a yearly basis) (Henson et al., 2016).

2. Methodology

The Sarcoma European Latin-American Network (SELNET), aims to improve clinical outcome in sarcoma care, with a special focus in Latin-American countries.

These Clinical Practice Guidelines (CPG) have been agreed by a multidisciplinary group of the SELNET consortium, with representatives of all partner entities including patient's advocacy groups (SPAEN). These CPG are motivated and generated to offer the best standard approach, based on the highest levels of published evidence, to diagnosis, treatment and follow-up in bone sarcoma in the Latin-American context. The current SELNET consortium CPG should be ideally corroborated and endorsed at a national level. Several virtual meetings were held to elaborate a draft of the guidelines and an on-site consensus meeting was celebrated in Lyon (France). Final version of the guidelines was circulated and agreed by all CPG working group members.

Levels of evidence and grades of recommendations have followed the system depicted in Table 1. Statements without grading were approved by consensus and considered as standard routine clinical practice by the experts.

Acknowledgements

The authors would like to thank the SELNET project, which has received funding from the EU Horizon 2020 research and innovation programme (grant number 825806).

References

- Abdul-Karim, F.W., Bauer, T.W., Kilpatrick, S.E., Raymond, K.A., Siegal, G.P., 2004. Recommendations for the reporting of bone tumors. Association of directors of anatomic and surgical pathology (Pathology, A. of D. of A. and S.). *Hum. Pathol.* 35, 1173–1178. <https://doi.org/10.1016/j.humpath.2004.07.004>.
- Amelio, J.M., Rockberg, J., Hernandez, R.K., Sobocki, P., Stryker, S., Bach, B.A., Engellau, J., Liede, A., 2016. Population-based study of giant cell tumor of bone in Sweden (1983–2011). *Cancer Epidemiol.* 42, 82–89. <https://doi.org/10.1016/j.canep.2016.03.014>.
- Andreou, D., Bielack, S.S., Carrle, D., Kevric, M., Kotz, R., Winkelmann, W., Jundt, G., Werner, M., Fehlbeg, S., Kager, L., Kühne, T., Lang, S., Dominkus, M., Exner, G.U., Harges, J., Hillmann, A., Ewerbeck, V., Heise, U., Reichardt, P., Tunn, P.U., 2011. The influence of tumor- and treatment-related factors on the development of local recurrence in osteosarcoma after adequate surgery. An analysis of 1355 patients treated on neoadjuvant Cooperative Osteosarcoma Study Group protocols. *Ann. Oncol.* 22, 1228–1235. <https://doi.org/10.1093/annonc/mdq589>.
- Antonescu, C.R., Owosho, A.A., Zhang, L., Chen, S., Deniz, K., Huryh, J.M., Kao, Y.C., Huang, S.C., Singer, S., Tap, W., Schaefer, I.M., Fletcher, C.D., 2017. Sarcomas with CIC-rearrangements are a distinct pathologic entity with aggressive outcome: a clinicopathologic and molecular study of 115 cases. *Am. J. Surg. Pathol.* 41, 941–949. <https://doi.org/10.1097/PAS.0000000000000846>.
- Bacci, G., Ferrari, S., Bertoni, F., Rimondini, S., Longhi, A., Bacchini, P., Forni, C., Manfrini, M., Donati, D., Picci, P., 2000. Prognostic factors in nonmetastatic Ewing's sarcoma of bone treated with adjuvant chemotherapy: analysis of 359 patients at the Istituto Ortopedico Rizzoli. *J. Clin. Oncol.* 18, 4–11. <https://doi.org/10.1200/JCO.2000.18.1.4>.
- Bacci, G., Forni, C., Longhi, A., Ferrari, S., Donati, D., De Paolis, M., Barbieri, E., Pignotti, E., Rosito, P., Versari, M., 2004. Long-term outcome for patients with non-metastatic Ewing's sarcoma treated with adjuvant chemotherapies. 402 patients treated at Rizzoli between 1972 and 1992. *Eur. J. Cancer* 40, 73–83. <https://doi.org/10.1016/j.ejca.2003.08.022>.
- Barnett, J.R., Gikas, P., Gerrand, C., Briggs, T.W., Saifuddin, A., 2020. The sensitivity, specificity, and diagnostic accuracy of whole-bone MRI for identifying skip metastases in appendicular osteosarcoma and Ewing sarcoma. *Skeletal Radiol.* 49, 913–919. <https://doi.org/10.1007/s00256-019-03364-0>.
- Basile, P., Greengard, E., Weigel, B., Spector, L., 2020. Prognostic factors for development of subsequent metastases in localized osteosarcoma: a systematic review and identification of literature gaps. *Sarcoma* 2020, 7431549. <https://doi.org/10.1155/2020/7431549>.
- Behjati, S., Tarpey, P.S., Presneau, N., Scheipl, S., Pillay, N., Van Loo, P., Wedge, D.C., Cooke, S.L., Gundem, G., Davies, H., Nik-Zainal, S., Martin, S., McLaren, S., Goodie, V., Robinson, B., Butler, A., Teague, J.W., Halai, D., Khatri, B., Myklebost, O., Baumhoer, D., Jundt, G., Hamoudi, R., Tirabosco, R., Amary, M.F., Futreal, P.A., Stratton, M.R., Campbell, P.J., Flanagan, A.M., 2013. Distinct H3F3A and H3F3B driver mutations define chondroblastoma and giant cell tumor of bone. *Nat. Genet.* 45, 1479–1482. <https://doi.org/10.1038/ng.2814>.
- Berger, M., Massimo, B., Grignani, G., Giovanni, G., Ferrari, S., Stefano, F., Biasin, E., Eleonora, B., Brach del Prever, A., Adalberto, B., el, P., Aliberti, S., Sandra, A., Saglio, F., Francesco, S., Aglietta, M., Massimo, A., Fagioli, F., Franca, F., 2009. Phase 2 trial of two courses of cyclophosphamide and etoposide for relapsed high-risk osteosarcoma patients. *Cancer* 115, 2980–2987. <https://doi.org/10.1002/cncr.24368>.
- Berner, K., Johannessen, T.B., Berner, A., Haugland, H.K., Bjerkehegen, B., Böhler, P.J., Bruland, Ø.S., 2015. Time-trends on incidence and survival in a nationwide and unselected cohort of patients with skeletal osteosarcoma. *Acta Oncol.* 54, 25–33. <https://doi.org/10.3109/0284186X.2014.923934>.
- Berenthal, N.M., Federman, N., Eilber, F.R., Nelson, S.D., Eckardt, J.J., Eilber, F.C., Tap, W.D., 2012. Long-term results (>25 years) of a randomized, prospective clinical trial evaluating chemotherapy in patients with high-grade, operable osteosarcoma. *Cancer* 118, 5888–5893. <https://doi.org/10.1002/cncr.27651>.
- Bielack, S.S., Kempf-Bielack, B., Delling, G., Exner, G.U., Flege, S., Helmke, K., Kotz, R., Salzer-Kuntschik, M., Werner, M., Winkelmann, W., Zoubek, A., Jürgens, H., Winkler, K., 2002. Prognostic factors in high-grade osteosarcoma of the extremities or trunk: an analysis of 1,702 patients treated on neoadjuvant cooperative osteosarcoma study group protocols. *J. Clin. Oncol.* 20, 776–790. <https://doi.org/10.1200/JCO.2002.20.3.776>.
- Bielack, S.S., Machatschek, J.N., Flege, S., Jürgens, H., 2004. Delaying surgery with chemotherapy for osteosarcoma of the extremities. *Expert Opin. Pharmacother.* 5, 1243–1256. <https://doi.org/10.1517/14656566.5.6.1243>.

- Bielack, S.S., Smeland, S., Whelan, J.S., Marina, N., Jovic, G., Hook, J.M., Krailo, M.D., Gebhardt, M., Pápai, Z., Meyer, J., Nadel, H., Randall, R.L., Deffenbaugh, C., Nagarajan, R., Brennan, B., Letson, G.D., Teot, L.A., Goorin, A., Baumhoer, D., Kager, L., Werner, M., Lau, C.C., Sundby Hall, K., Gelderblom, H., Meyers, P., Gorlick, R., Windhager, R., Helmke, K., Eriksson, M., Hoogerbrugge, P.M., Schomberg, P., Tunn, P.U., Kühne, T., Jürgens, H., van den Berg, H., Böhlting, T., Picton, S., Renard, M., Reichardt, P., Gerss, J., Butterfass-Bahloul, T., Morris, C., Hogendoorn, P.C., Seddon, B., Calaminus, G., Michelagnoli, M., Dhooge, C., Sydes, M.R., Bernstein, M., investigators, E.-1, 2015. Methotrexate, Doxorubicin, and Cisplatin (MAP) plus maintenance pegylated interferon alfa-2b versus map alone in patients with resectable high-grade osteosarcoma and good histologic response to preoperative MAP: first results of the EURAMOS-1 good response randomized controlled trial. *J. Clin. Oncol.* 33, 2279–2287. <https://doi.org/10.1200/JCO.2014.60.0734>.
- Blay, J.-Y., Soibinet, P., Penel, N., Bompas, E., Duffaud, F., Stoeckle, E., Mir, O., Adam, J., Chevreau, C., Bonvalot, S., Rios, M., Kerbrat, P., Cupissol, D., Anract, P., Gouin, F., Kurtz, J.E., Lebbe, C., Isambert, N., Bertucci, F., Toumonde, M., Thyss, A., Piperno-Neumann, S., Dubray-Longeras, P., Meeus, P., Ducimetière, F., Giraud, A., Coindre, J.M., Ray-Coquard, I., Italiano, A., Le Cesne, A., 2017. Improved survival using specialized multidisciplinary board in sarcoma patients. *Ann. Oncol.* 28, 2852–2859. <https://doi.org/10.1093/annonc/mdx484>.
- Blay, J.-Y., Honoré, C., Stoeckle, E., Meeus, P., Jafari, M., Gouin, F., Anract, P., Ferron, G., Rochwerger, A., Ropars, M., Carrere, S., Marchal, F., Sirveaux, F., Di Marco, A., Le Nail, L.R., Guirmand, J., Vaz, G., Machiavello, J.-C., Marco, O., Causseret, S., Gimbergues, P., Fiorenza, F., Chaigneau, L., Guillemin, F., Guilloit, J.-M., Dujardin, F., Spano, J.-P., Ruzic, J.-C., Michot, A., Soibinet, P., Bompas, E., Chevreau, C., Duffaud, F., Rios, M., Perrin, C., Firmin, N., Bertucci, F., Le Pechoux, C., Le Loarer, F., Collard, O., Karanian-Philippe, M., Brahm, M., Dufresne, A., Dupré, A., Ducimetière, F., Giraud, A., Pérol, D., Toulmonde, M., Ray-Coquard, I., Italiano, A., Le Cesne, A., Penel, N., Bonvalot, S., 2019. Surgery in reference centers improves survival of sarcoma patients: a nationwide study. *Ann. Oncol.* 30, 1407. <https://doi.org/10.1093/annonc/mdz170>.
- Board, W.C. of T.E., n.d. Soft Tissue and Bone Tumours.
- Bölling, T., Schuck, A., Paulussen, M., Dirksen, U., Ranft, A., Könemann, S., Dunst, J., Willich, N., Jürgens, H., 2008. Whole lung irradiation in patients with exclusively pulmonary metastases of Ewing tumors. Toxicity analysis and treatment results of the EICESS-92 trial. *Strahlenther Onkol* 184, 193–197. <https://doi.org/10.1007/s00066-008-1810-x>.
- Bompas, E., Le Cesne, A., Tresch-Bruneel, E., Lebellet, L., Laurence, V., Collard, O., Saada-Bouzid, E., Isambert, N., Blay, J.-Y., Amela, E.Y., Salas, S., Chevreau, C., Bertucci, F., Italiano, A., Clisant, S., Penel, N., 2015. Sorafenib in patients with locally advanced and metastatic chondrosarcoma: a phase II trial of the French Sarcoma Group (GSF/GETO). *Ann. Oncol.* 26, 2168–2173. <https://doi.org/10.1093/annonc/mdv300>.
- Bovee, J., Bloem, J., Flanagan, A., Nielsen, G., Yoshida, A., 2020. Central atypical cartilaginous tumors/chondrosarcoma, grade I. In: WHO Classification of Tumours 5th Edition. Soft Tissue and Bone Tumours. International Agency for Research on Cancer, Lyon, pp. 370–372.
- Bramer, J.A., van Linge, J.H., Grimer, R.J., Scholten, R.J., 2009. Prognostic factors in localized extremity osteosarcoma: a systematic review. *Eur. J. Surg. Oncol.* 35, 1030–1036. <https://doi.org/10.1016/j.ejso.2009.01.011>.
- Bramwell, V.H., Steward, W.P., Nooij, M., Whelan, J., Craft, A.W., Grimer, R.J., Taminau, A.H., Cannon, S.R., Malcolm, A.J., Hogendoorn, P.C., Uscinska, B., Kirkpatrick, A.L., Machin, D., Van Glabbeke, M.M., 1999. Neoadjuvant chemotherapy with doxorubicin and cisplatin in malignant fibrous histiocytoma of bone: A European Osteosarcoma Intergroup study. *J. Clin. Oncol.* 17, 3260–3269. <https://doi.org/10.1200/JCO.1999.17.10.3260>.
- Brennan, B., Marec-Berard, Laura, Martin-Broto, Perrine, Gelderblom, Javier, Gaspar, Hans, Strauss, Nathalie, JSastre Urgelles, Sandra, Anderton, Ana, Laurence, Jennifer, Whelan, Valerie, Wheatley, Jeremy, Keith, 2020. Comparison of two chemotherapy regimens in Ewing sarcoma (ES): Overall and subgroup results of the Euro Ewing 2012 randomized trial (EE2012). *J. Clin. Oncol.* 38, 11500. <https://doi.org/10.1200/JCO.2020.38.15.suppl.11500>.
- Bridge, J.A., Sumegi, J., Druta, M., Bui, M.M., Henderson-Jackson, E., Linos, K., Baker, M., Walko, C.M., Millis, S., Brohl, A.S., 2019. Clinical, pathological, and genomic features of EWSR1-PATZ1 fusion sarcoma. *Mod. Pathol.* 32, 1593–1604. <https://doi.org/10.1038/s41379-019-0301-1>.
- Buchbender, C., Heusner, T.A., Lauenstein, T.C., Bockisch, A., Antoch, G., 2012. Oncologic PET/MRI, part 2: bone tumors, soft-tissue tumors, melanoma, and lymphoma. *J. Nucl. Med.* 53, 1244–1252. <https://doi.org/10.2967/jnumed.112.109306>.
- Carrle, D., Bielack, S.S., 2006. Current strategies of chemotherapy in osteosarcoma. *Int. Orthop.* 30, 445–451. <https://doi.org/10.1007/s00264-006-0192-x>.
- Casali, P.G., Bielack, S., Abecassis, N., Aro, H.T., Bauer, S., Biagini, R., Bonvalot, S., Boukovinas, I., Bovee, J., Brennan, B., Brodowicz, T., Broto, J.M., Brugieres, L., Buonadonna, A., De Alava, E., Dei Tos, A.P., Del Muro, X.G., Dileo, P., Dhooge, C., Eriksson, M., Fagioli, F., Fedenko, A., Ferraresi, V., Ferrari, A., Ferrari, S., Frezza, A. M., Gaspar, N., Gasperoni, S., Gelderblom, H., Gil, T., Grignani, G., Gronchi, A., Haas, R.L., Hassan, B., Hecker-Nolting, S., Hohenberger, P., Issels, R., Joensuu, H., Jones, R.L., Judson, I., Jutte, P., Kaal, S., Kager, L., Kasper, B., Kopeckova, K., Krakorova, D.A., Ladenstein, R., Le Cesne, A., Lugoowska, I., Merimsky, O., Montemurro, M., Morland, B., Pantaleo, M.A., Piana, R., Picci, P., Piperno-Neumann, S., Pousa, A.L., Reichardt, P., Robinson, M.H., Rutkowski, P., Safwat, A. A., Schoffski, P., Sleijfer, S., Stacchiotti, S., Strauss, S.J., Sundby Hall, K., Unk, M., Van Coevorden, F., van der Graaf, W.T.A., Whelan, J., Wardelmann, E., Zaikova, O., Blay, J.-Y., 2018. Bone sarcomas: ESMO-PaedCan-EURACAN clinical practice guidelines for diagnosis, treatment and follow-up (Esmo Guidelines Committee, P., Ern, E.). *Ann. Oncol.* 29 iv79–iv95. <https://doi.org/10.1093/annonc/mdy310>.
- Cesari, M., Righti, A., Colangeli, M., Gambarotti, M., Ferraro, P., Longhi, A., Palmerini, M. E., Paioli, A., Ferrari, C., Donati, D.M., Picci, P., Ferrari, S., 2019. Bone marrow biopsy in the initial staging of Ewing sarcoma: Experience from a single institution. *Pediatr. Blood Cancer* 66 (6), e27653.
- Cesari, M., Alberghini, M., Vanel, D., Palmerini, E., Staals, E.L., Longhi, A., Abate, M., Ferrari, C., Balladelli, A., Ferrari, S., 2011. Periosteal osteosarcoma: a single-institution experience. *Cancer* 117, 1731–1735. <https://doi.org/10.1002/cncr.25718>.
- Chawla, S., Blay, J.-Y., Rutkowski, P., Le Cesne, A., Reichardt, P., Gelderblom, H., Grimer, R.J., Choy, E., Skubitz, K., Seeger, L., Schuetz, S.M., Henshaw, R., Dai, T., Jandial, D., Palmerini, E., 2019. Denosumab in patients with giant-cell tumour of bone: a multicentre, open-label, phase 2 study. *Lancet Oncol.* 20, 1719–1729. [https://doi.org/10.1016/S1470-2045\(19\)30663-1](https://doi.org/10.1016/S1470-2045(19)30663-1).
- Chen, X., Yu, L.J., Peng, H.M., Jiang, C., Ye, C.H., Zhu, S.B., Qian, W.W., 2017. Is intralesional resection suitable for central grade 1 chondrosarcoma: A systematic review and updated meta-analysis. *Eur. J. Surg. Oncol.* 43, 1718–1726. <https://doi.org/10.1016/j.ejso.2017.05.022>.
- Cotterill, S.J., Ahrens, S., Paulussen, M., Jürgens, H.F., Voûte, P.A., Gardner, H., Craft, A. W., 2000. Prognostic factors in Ewing's tumor of bone: analysis of 975 patients from the European Intergroup Cooperative Ewing's Sarcoma Study Group. *J. Clin. Oncol.* 18, 3108–3114. <https://doi.org/10.1200/JCO.2000.18.17.3108>.
- D, E., YM, S., MJ, G., et al., 2009. Assessment of interobserver variability and histologic parameters to improve reliability in classification and grading of central cartilaginous tumors. *Am. J. Surg. Pathol.* 33, 50–57.
- Dantonello, T.M., Int-Veen, C., Leuschner, I., Schuck, A., Furtwaengler, R., Claviez, A., Schneider, D.T., Klingebiel, T., Biela, S.S., Koscielniak, E., 2008. Mesenchymal chondrosarcoma of soft tissues and bone in children, adolescents, and young adults: experiences of the CWS and COSS study groups (group, CWS study, group, COSS study). *Cancer* 112, 2424–2431. <https://doi.org/10.1002/cncr.23457>.
- Delaney, T.F., Liebsch, N.J., Pedlow, F.X., Adams, J., Weyman, E.A., Yeap, B.Y., Depauw, N., Nielsen, G.P., Harmon, D.C., Yoon, S.S., Chen, Y.L., Schwab, J.H., Hornicek, F.J., 2014. Long-term results of Phase II study of high dose photon/proton radiotherapy in the management of spine chordomas, chondrosarcomas, and other sarcomas. *J. Surg. Oncol.* 110, 115–122. <https://doi.org/10.1002/jso.23617>.
- Dickey, I.D., Rose, P.S., Fuchs, B., Wold, L.E., Okuno, S.H., Sim, F.H., Scully, S.P., 2004. Dedifferentiated chondrosarcoma: the role of chemotherapy with updated outcomes. *J. Bone Joint Surg. Am.* 86, 2412–2418.
- Duffaud, F., Blay, J., Italiano, A., Bompas, E., Rios, M., Penel, N., Mir, O., Piperno-Neumann, S., Chevreau, C.M., Delcambre, C., Bertucci, F., Rouquette, P.B., Vegas, H., Perrin, C., Thyss, A., Schiffer, C., Monard, L., Bouvier, C., Vidal, V., Chabaud, S., 2019. Results of the randomized, Placebo (PL)-Controlled phase II study evaluating the efficacy and safety of Regorafenib (REG) in Patients (PTS) with locally advanced (LA) or metastatic relapsed chondrosarcoma (CS), on behalf of the French Sarcoma Group (FSG) and UNICANCER. *Ann. Oncol.* 30.
- Duffaud, Florence, Mir, O., Boudou-Rouquette, P., Piperno-Neumann, S., Penel, N., Bompas, E., Delcambre, C., Kalbacher, E., Italiano, A., Collard, O., Chevreau, C., Saada, E., Isambert, N., Delaye, J., Schiffer, C., Bouvier, C., Vidal, V., Chabaud, S., Blay, J.-Y., 2019. Efficacy and safety of regorafenib in adult patients with metastatic osteosarcoma: a non-comparative, randomised, double-blind, placebo-controlled, phase 2 study (French Sarcoma Group). *Lancet Oncol.* 20, 120–133. [https://doi.org/10.1016/S1470-2045\(18\)30742-3](https://doi.org/10.1016/S1470-2045(18)30742-3).
- Enneking, W.F., Spanier, S.S., Goodman, M.A., 1980. A system for the surgical staging of musculoskeletal sarcoma. *Clin. Orthop. Relat. Res.* 106–120.
- Fagioli, F., Aglietta, M., Tienghi, A., Ferrari, S., Brach del Prever, A., Vassallo, E., Palmero, A., Biasin, E., Bacci, G., Picci, P., Madon, E., 2002. High-dose chemotherapy in the treatment of relapsed osteosarcoma: an Italian sarcoma group study. *J. Clin. Oncol.* 20, 2150–2156. <https://doi.org/10.1200/JCO.2002.08.081>.
- Ferrari, D., Monaghini, L., Allevi, F., Biglioli, G.B. and F., 2017. Osteosarcoma of the Jaw: Classification, Diagnosis and Treatment, Osteosarcoma - Biology, Behavior and Mechanisms. *IntechOpen*. <https://doi.org/10.5772/67564>.
- Ferrari, S., Briccoli, A., Mercuri, M., Bertoni, F., Picci, P., Tienghi, A., Del Prever, A.B., Fagioli, F., Comandone, A., Bacci, G., 2003. Postrelapse survival in osteosarcoma of the extremities: prognostic factors for long-term survival. *J. Clin. Oncol.* 21, 710–715. <https://doi.org/10.1200/JCO.2003.03.141>.
- Ferrari, S., Smeland, S., Mercuri, M., Bertoni, F., Longhi, A., Ruggieri, P., Alvegard, T.A., Picci, P., Capanna, R., Bernini, G., Müller, C., Tienghi, A., Wiebe, T., Comandone, A., Böhlting, T., Del Prever, A.B., Brosjö, O., Bacci, G., Saeter, G., Groups, I., S. S., 2005. Neoadjuvant chemotherapy with high-dose ifosfamide, high-dose methotrexate, cisplatin, and doxorubicin for patients with localized osteosarcoma of the extremity: a joint study by the Italian and Scandinavian Sarcoma Groups. *J. Clin. Oncol.* 23, 8845–8852. <https://doi.org/10.1200/JCO.2004.00.5785>.
- Ferrari, S., del Prever, A.B., Palmerini, E., Staals, E., Berta, M., Balladelli, A., Picci, P., Fagioli, F., Bacci, G., Vanel, D., 2009. Response to high-dose ifosfamide in patients with advanced/recurrent Ewing sarcoma. *Pediatr. Blood Cancer* 52, 581–584. <https://doi.org/10.1002/psc.21917>.
- Ferrari, S., Sundby Hall, K., Luksch, R., Tienghi, A., Wiebe, T., Fagioli, F., Alvegard, T.A., Brach Del Prever, A., Tamburini, A., Alberghini, M., Gandola, L., Mercuri, M., Capanna, R., Mapelli, S., Prete, A., Carli, M., Picci, P., Barbieri, E., Bacci, G., Smeland, S., 2011. Nonmetastatic Ewing family tumors: high-dose chemotherapy with stem cell rescue in poor responder patients. Results of the Italian Sarcoma Group/Scandinavian Sarcoma Group III protocol. *Ann. Oncol.* 22, 1221–1227. <https://doi.org/10.1093/annonc/mdq573>.
- Ferrari, S., Bielack, S.S., Smeland, S., Longhi, A., Egerer, G., Sundby Hall, K., Donati, D., Kevric, M., Brosjö, O., Comandone, A., Werner, M., Monge, O., Palmerini, E.,

- Berdel, W.E., Bjerkeheggen, B., Paioli, A., Lorenzen, S., Eriksson, M., Gambarotti, M., Tunn, P.U., Jebsen, N.L., Cesari, M., von Kalle, T., Ferraresi, V., Schwarz, R., Bertulli, R., Kasperek, A.K., Grignani, G., Krasniqi, F., Sorg, B., Hecker-Nolting, S., Picci, P., Reichardt, P., 2018. EURO-B.O.S.S.: A European study on chemotherapy in bone-sarcoma patients aged over 40: Outcome in primary high-grade osteosarcoma. *Tumori* 104, 30–36. <https://doi.org/10.5301/tj.5000696>.
- Ferrer-Santacreu, E.M., Ortiz-Cruz, E.J., Díaz-Almirón, M., Pozo Kreilinger, J.J., 2016. Enchondroma versus chondrosarcoma in long bones of appendicular skeleton: clinical and radiological criteria—a follow-up. *J. Oncol.* 2016, 8262079 <https://doi.org/10.1155/2016/8262079>.
- Fiorenza, F., Abudu, A., Grimer, R.J., Carter, S.R., Tillman, R.M., Ayoub, K., Mangham, D.C., Davies, A.M., 2002. Risk factors for survival and local control in chondrosarcoma of bone. *J. Bone Joint Surg. Br.* 84, 93–99. <https://doi.org/10.1302/0301-620x.84b1.11942>.
- Fox, E., Patel, S., Wathen, J.K., Schuetz, S., Chawla, S., Harmon, D., Reinke, D., Chugh, R., Benjamin, R.S., Helman, L.J., 2012. Phase II study of sequential gemcitabine followed by docetaxel for recurrent Ewing sarcoma, osteosarcoma, or unresectable or locally recurrent chondrosarcoma: results of Sarcoma Alliance for Research Through Collaboration Study 003. *Oncologist* 17, 321. <https://doi.org/10.1634/theoncologist.2010-0265>.
- Frezza, A.M., Beale, T., Bomanji, J., Jay, A., Kalavrezos, N., Dileo, P., Whelan, J., Strauss, S.J., 2014. Is [F-18]-fluorodeoxy-D-glucose positron emission tomography of value in the management of patients with craniofacial bone sarcomas undergoing neo-adjuvant treatment? *BMC Cancer* 14, 23. <https://doi.org/10.1186/1471-2407-14-23>.
- Frezza, A.M., Cesari, M., Baumhoer, D., Biau, D., Bielack, S., Campanacci, D.A., Casanova, J., Esler, C., Ferrari, S., Funovics, P.T., Gerrand, C., Grimer, R., Gronchi, A., Haffner, N., Hecker-Nolting, S., Höller, S., Jeys, L., Jutte, P., Leithner, A., San-Julian, M., Thorkildsen, J., Vincenzi, B., Windhager, R., Whelan, J., 2015. Mesenchymal chondrosarcoma: prognostic factors and outcome in 113 patients. A European Musculoskeletal Oncology Society study. *Eur. J. Cancer* 51, 374–381. <https://doi.org/10.1016/j.ejca.2014.11.007>.
- Gaspar, N., Hawkins, D.S., Dirksen, U., Lewis, I.J., Ferrari, S., Le Deley, M.C., Kovar, H., Grimer, R., Whelan, J., Claude, L., Delattre, O., Paulussen, M., Picci, P., Sundby Hall, K., van den Berg, H., Ladenstein, R., Michon, J., Hjorth, L., Judson, I., Luksch, R., Bernstein, M.L., Marec-Bérard, P., Brennan, B., Craft, A.W., Womer, R.B., Juergens, H., Oberlin, O., 2015. Ewing sarcoma: current management and future approaches through collaboration. *J. Clin. Oncol.* 33, 3036–3046. <https://doi.org/10.1200/JCO.2014.59.5256>.
- Gelderblom, H., Hogendoorn, P.C., Dijkstra, S.D., van Rijswijk, C.S., Krol, A.D., Taminiau, A.H., Bovée, J.V., 2008. The clinical approach towards chondrosarcoma. *Oncologist* 13, 320–329. <https://doi.org/10.1634/theoncologist.2007-0237>.
- Gentet, J.C., Brunat-Mentigny, M., Demaille, M.C., Pein, F., Avet-Loiseau, H., Berger, C., De Lumley, L., Pacquement, H., Schmitt, C., Sariban, E., Pillon, P., Bernard, J.L., Kalifa, C., 1997. Ifosfamide and etoposide in childhood osteosarcoma. A phase II study of the French Society of Paediatric Oncology. *Eur. J. Cancer* 33, 232–237. [https://doi.org/10.1016/s0959-8049\(96\)00439-x](https://doi.org/10.1016/s0959-8049(96)00439-x).
- Goorin, A.M., Schwartztruber, D.J., Devidas, M., Gebhardt, M.C., Ayala, A.G., Harris, M.B., Helman, L.J., Grier, H.E., Link, M.P., Group, P.O., 2003. Presurgical chemotherapy compared with immediate surgery and adjuvant chemotherapy for nonmetastatic osteosarcoma: Pediatric Oncology Group Study POG-8651. *J. Clin. Oncol.* 21, 1574–1580. <https://doi.org/10.1200/JCO.2003.08.165>.
- Grier, H.E., Krailo, M.D., Tarbell, N.J., Link, M.P., Fryer, C.J., Pritchard, D.J., Gebhardt, M.C., Dickman, P.S., Perlman, E.J., Meyers, P.A., Donaldson, S.S., Moore, S., Rausen, A.R., Vietti, T.J., Miser, J.S., 2003. Addition of ifosfamide and etoposide to standard chemotherapy for Ewing's sarcoma and primitive neuroectodermal tumor of bone. *N. Engl. J. Med.* 348, 694–701. <https://doi.org/10.1056/NEJMoa020890>.
- Grignani, G., Palmerini, E., Ferraresi, V., D'Ambrosio, L., Bertulli, R., Asaftei, S.D., Tamburini, A., Pignochino, Y., Sangiolo, D., Marchesi, E., Capozzi, F., Biagini, R., Gambarotti, M., Fagioli, F., Casali, P.G., Picci, P., Ferrari, S., Aglietta, M., Group, I.S., 2015. Sorafenib and everolimus for patients with unresectable high-grade osteosarcoma progressing after standard treatment: a non-randomised phase 2 clinical trial. *Lancet Oncol.* 16, 98–107. [https://doi.org/10.1016/S1470-2045\(14\)71136-2](https://doi.org/10.1016/S1470-2045(14)71136-2).
- Grimer, R.J., Bielack, S., Flege, S., Cannon, S.R., Folaras, G., Andreff, I., Sokolov, T., Taminiau, A., Dominkus, M., San-Julian, M., Kollender, Y., Gosheger, G., Society, E. M.S.O., 2005. Periosteal osteosarcoma—a European review of outcome. *Eur. J. Cancer* 41, 2806–2811. <https://doi.org/10.1016/j.ejca.2005.04.052>.
- Grimer, R.J., Gosheger, G., Taminiau, A., Biau, D., Matejovsky, Z., Kollender, Y., San-Julian, M., Gherlinzoni, F., Ferrari, C., 2007. Dedifferentiated chondrosarcoma: prognostic factors and outcome from a European group. *Eur. J. Cancer* 43, 2060–2065. <https://doi.org/10.1016/j.ejca.2007.06.016>.
- Haeussler, J., Ranft, A., Boelling, T., Gosheger, G., Braun-Munzinger, G., Vieth, V., Burdach, S., van den Berg, H., Juergens, H., Dirksen, U., 2010. The value of local treatment in patients with primary, disseminated, multifocal Ewing sarcoma (PDMES). *Cancer* 116, 443–450. <https://doi.org/10.1002/cncr.24740>.
- Heck, R.K., Peabody, T.D., Simon, M.A., 2006. Staging of primary malignancies of bone. *CA Cancer J. Clin.* 56, 366–375. <https://doi.org/10.3322/canjclin.56.6.366>.
- Henson, K.E., Reulen, R.C., Winter, D.L., Bright, C.J., Fidler, M.M., Frohisher, C., Guha, J., Wong, K.F., Kelly, J., Edgar, A.B., McCabe, M.G., Whelan, J., Cutter, D.J., Darby, S.C., Hawkins, M.M., 2016. Cardiac Mortality Among 200 000 Five-Year Survivors of Cancer Diagnosed at 15 to 39 Years of Age: The Teenage and Young Adult Cancer Survivor Study. *Circulation* 134, 1519–1531. <https://doi.org/10.1161/CIRCULATIONAHA.116.022514>.
- Hurley, C., McCarville, M.B., Shulkin, B.L., Mao, S., Wu, J., Navid, F., Daw, N.C., Pappo, A.S., Bishop, M.W., 2016. Comparison of (18) F-FDG-PET-CT and Bone Scintigraphy for Evaluation of Osseous Metastases in Newly Diagnosed and Recurrent Osteosarcoma. *Pediatr. Blood Cancer* 63, 1381–1386. <https://doi.org/10.1002/psc.26014>.
- Italiano, A., Mir, O., Cioffi, A., Palmerini, E., Piperno-Neumann, S., Perrin, C., Chaigneau, L., Penel, N., Duffaud, F., Kurtz, J.E., Collard, O., Bertucci, F., Bompas, E., Le Cesne, A., Maki, R.G., Ray Coquard, I., Blay, J.Y., 2013. Advanced chondrosarcomas: role of chemotherapy and survival. *Ann. Oncol.* 24, 2916–2922. <https://doi.org/10.1093/annonc/mdt374>.
- Jawad, M.U., Cheung, M.C., Min, E.S., Schneiderbauer, M.M., Koniaris, L.G., Scully, S.P., 2009. Ewing sarcoma demonstrates racial disparities in incidence-related and sex-related differences in outcome: an analysis of 1631 cases from the SEER database, 1973–2005. *Cancer* 115, 3526–3536. <https://doi.org/10.1002/cncr.24388>.
- JD, B., MK, G. (Eds.), 2016. *TNM Classification of Malignant Tumours, 8th edn.* John Wiley & Sons, Inc, Oxford.
- Kao, Y.-C., Owosho, A.A., Sung, Y.-S., Zhang, L., Fujisawa, Y., Lee, J.-C., Wexler, L., Argani, P., Swanson, D., Dickson, B.C., Fletcher, C.D.M., Antonescu, C.R., 2018. BCOR-CCNB3 Fusion Positive Sarcomas: A Clinicopathologic and Molecular Analysis of 36 Cases With Comparison to Morphologic Spectrum and Clinical Behavior of Other Round Cell Sarcomas. *Am. J. Surg. Pathol.* 42, 604–615. <https://doi.org/10.1097/PAS.0000000000000965>.
- Laitinen, M., Parry, M., Albergo, J.I., Jeys, L., Abudu, A., Carter, S., Sumathi, V., Grimer, R., 2015. The prognostic and therapeutic factors which influence the oncological outcome of parosteal osteosarcoma. *Bone Joint J.* 97-B 1698–1703. <https://doi.org/10.1302/0301-620X.97B12.35749>.
- Le Deley, M.C., Delattre, O., Schaefer, K.L., Burchill, S.A., Koehler, G., Hogendoorn, P.C., Lion, T., Poremba, C., Marandet, J., Ballet, S., Pierron, G., Brownhill, S.C., Nesslböck, M., Ranft, A., Dirksen, U., Oberlin, O., Lewis, I.J., Craft, A.W., Jürgens, H., Kovar, H., 2010. Impact of EWS-ETS fusion type on disease progression in Ewing's sarcoma/peripheral primitive neuroectodermal tumor: prospective results from the cooperative Euro-E.W.I.N.G. 99 trial. *J. Clin. Oncol.* 28, 1982–1988. <https://doi.org/10.1200/JCO.2009.23.3585>.
- Leavey, P.J., Collier, A.B., 2008. Ewing sarcoma: prognostic criteria, outcomes and future treatment. *Expert Rev. Anticancer Ther.* 8, 617–624. <https://doi.org/10.1586/14737140.8.4.617>.
- Lebellec, L., Chaffert, B., Blay, J.Y., Le Cesne, A., Chevreau, C., Bompas, E., Bertucci, F., Cupissol, D., Fabbro, M., Saada-Bouaid, E., Duffaud, F., Feuvret, L., Bonneville-Levard, A., Bay, J.O., Vauleon, E., Vinceneux, A., Noel, G., Penel, N., Mir, O., 2017. Advanced chordoma treated by first-line molecular targeted therapies: Outcomes and prognostic factors. A retrospective study of the French Sarcoma Group (GSF/GETO) and the Association des Neuro-Oncologues d'Expression Française (ANOCEF). *Eur. J. Cancer* 79, 119–128.
- Leeraun, T., Hugate, R.R., Inwards, C.Y., Scully, S.P., Sim, F.H., 2007. Surgical management of conventional grade I chondrosarcoma of long bones. *Clin. Orthop. Relat. Res.* 463, 166–172. <https://doi.org/10.1097/BL0.0b013e318146830f>.
- Leroy, R., Benahmed, N., Hulstaert, F., Van Damme, N., De Ruyssecher, D., 2016. Proton therapy in children: a systematic review of clinical effectiveness in 15 pediatric cancers. *Int. J. Radiat. Oncol. Biol. Phys.* 95, 267–278. <https://doi.org/10.1016/j.ijrobp.2015.10.025>.
- Lewis, I.J., Nooij, M.A., Whelan, J., Sydes, M.R., Grimer, R., Hogendoorn, P.C., Memon, M.A., Weeden, S., Uscinska, B.M., van Glabbeke, M., Kirkpatrick, A., Hauben, E.L., Craft, A.W., Taminiau, A.H., collaborators, M.B., 2007. Improvement in histologic response but not survival in osteosarcoma patients treated with intensified chemotherapy: a randomized phase III trial of the European Osteosarcoma Intergroup, and E. 80931, Intergroup, E.O. J. Natl. Cancer Inst. 99, 112–128. <https://doi.org/10.1093/jnci/djk015>.
- Liede, A., Bach, B.A., Stryker, S., Hernandez, R.K., Sobocki, P., Bennett, B., Wong, S.S., 2014. Regional variation and challenges in estimating the incidence of giant cell tumor of bone. *J. Bone Joint Surg. Am.* 96, 1999–2007. <https://doi.org/10.2106/JBJS.N.00367>.
- Machado, I., Noguera, R., Pellin, A., Lopez-Guerrero, J.A., Piqueras, M., Navarro, S., Lombart-Bosch, A., 2009. Molecular diagnosis of Ewing sarcoma family of tumors: a comparative analysis of 560 cases with FISH and RT-PCR. *Diagn. Mol. Pathol.* 18, 189–199. <https://doi.org/10.1097/PDM.0b013e3181a06f66>.
- Mankin, H.J., Lange, T.A., Spanier, S.S., 2002. The hazards of biopsy in patients with malignant primary bone and soft-tissue tumors. *J. Bone Joint Surg. Am.* 64, 1121–1127.
- Marina, N.M., Smeland, S., Bielack, S.S., Bernstein, M., Jovic, G., Krailo, M.D., Hook, J. M., Arndt, C., van den Berg, H., Brennan, B., Brichard, B., Brown, K.L.B., Butterfass-Bahloul, T., Calaminus, G., Daldrup-Link, H.E., Eriksson, M., Gebhardt, M.C., Gelderblom, H., Gerss, J., Goldsby, R., Goorin, A., Gorlick, R., Grier, H.E., Hale, J.P., Hall, K.S., Harges, J., Hawkins, D.S., Helmeke, K., Hogendoorn, P.C.W., Isakoff, M.S., Janeway, K.A., Jürgens, H., Kager, L., Kühne, T., Lau, C.C., Leavey, P.J., Lessnick, S. L., Mascarenhas, L., Meyers, P.A., Mottl, H., Nathrath, M., Papai, Z., Randall, R.L., Reichardt, P., Renard, M., Safwat, A.A., Schwartz, C.L., Stevens, M.C.G., Strauss, S.J., Teot, L., Werner, M., Sydes, M.R., Whelan, J.S., 2016. Comparison of MAPIE versus MAP in patients with a poor response to preoperative chemotherapy for newly diagnosed high-grade osteosarcoma (EURAMOS-1): an open-label, international, randomised controlled trial. *Lancet Oncol.* 17, 1396–1408. [https://doi.org/10.1016/S1470-2045\(16\)30214-5](https://doi.org/10.1016/S1470-2045(16)30214-5).
- McCabe, M.G., Moroz, V., Khan, M., Dirksen, U., Evans, A., Fenwick, N., Gaspar, N., Kanerva, J., Kühne, T., Longhi, A., Luksch, R., Mata, C., Phillips, M., Sundby Hall, K., Valverde Morales, C.M., Westwood, A.J., Winstanley, M., Whelan, J., Wheatley, K., 2019. Results of the first interim assessment of rEECur, an international randomized controlled trial of chemotherapy for the treatment of recurrent and primary

- refractory Ewing sarcoma. *JCO* 37. https://doi.org/10.1200/JCO.2019.37.15_suppl.11007.
- McCabe, M.G., Kirton, L., Khan, M., Fenwick, N., Dirksen, U., Gaspar, N., Kanerva, J., Kuehne, T., Longhi, A., Luksch, R., Mata, C., Phillips, M., Safwat, A., Strauss, S.J., Sundby Hall, K., Valverde Morales, C.M., Westwood, A.J., Winstanley, M., Whelan, J., Wheatley, K., 2020. Results of the second interim assessment of rEECur, an international randomized controlled trial of chemotherapy for the treatment of recurrent and primary refractory Ewing sarcoma (RR-ES). *JCO* 38. https://doi.org/10.1200/JCO.2020.38.15_suppl.11502.
- Meyer, J.S., Nadel, H.R., Marina, N., Womer, R.B., Brown, K.L., Eary, J.F., Gorlick, R., Grier, H.E., Randall, R.L., Lawlor, E.R., Lessnick, S.L., Schomberg, P.J., Kailo, M.D., 2008. Imaging guidelines for children with Ewing sarcoma and osteosarcoma: a report from the Children's Oncology Group Bone Tumor Committee. *Pediatr. Blood Cancer* 51, 163–170. <https://doi.org/10.1002/pbc.21596>.
- Meyers, P.A., Schwartz, C.L., Krailo, M.D., Healey, J.H., Bernstein, M.L., Betcher, D., Ferguson, W.S., Gebhardt, M., Goorin, A.M., Harris, M., Kleinerman, E., Link, M.P., Nadel, H., Nieder, M., Siegal, G.P., Weiner, M.A., Wells, R.J., Womer, R.B., Grier, H. E., Group, C.O., 2008. Osteosarcoma: the addition of muramyl tripeptide to chemotherapy improves overall survival—a report from the Children's Oncology Group. *J. Clin. Oncol.* 26, 633–638. <https://doi.org/10.1200/JCO.2008.14.0095>.
- Mirabello, L., Troisi, R.J., Savage, S.A., 2009. International osteosarcoma incidence patterns in children and adolescents, middle ages and elderly persons. *Int. J. Cancer* 125, 229–234. <https://doi.org/10.1002/ijc.24320>.
- Moreno, F., Cacciavillano, W., Cipolla, M., Coirini, M., Streitenberger, P., López Martí, J., Palladino, M., Morici, M., Onoratielli, M., Drago, G., Schifano, A., Cores, M., Rose, A., Jotomliansky, J., Varel, M., García Lombardi, M., 2017. Childhood osteosarcoma: Incidence and survival in Argentina. Report from the National Pediatric Cancer Registry, ROHA Network 2000–2013. *Pediatr. Blood Cancer* 64. <https://doi.org/10.1002/pbc.26533>.
- Nesbit, M.E., Gehan, E.A., Burgert, E.O., Vietti, T.J., Cangir, A., Tefft, M., Evans, R., Thomas, P., Askin, F.B., Kissane, J.M., 1990. Multimodal therapy for the management of primary, nonmetastatic Ewing's sarcoma of bone: a long-term follow-up of the First Intergroup study. *J. Clin. Oncol.* 8, 1664–1674. <https://doi.org/10.1200/JCO.1990.8.10.1664>.
- Noël, G., Feuvret, L., Ferrand, R., Boissierie, G., Mazon, J.J., Habrand, J.L., 2004. Radiotherapeutic factors in the management of cervical-basal chordomas and chondrosarcomas. discussion 1260-2 Neurosurgery 55, 1252–1260. <https://doi.org/10.1227/01.neu.0000143330.30405.a>.
- Nooij, M.A., Whelan, J., Bramwell, V.H.C., Taminiau, A.T., Cannon, S., Hogendoorn, P.C.W., Pringle, J., Uscinska, B.M., Weeden, S., Kirkpatrick, A., Glabbeke, M. v. Craft, A. W., 2005. Doxorubicin and cisplatin chemotherapy in high-grade spindle cell sarcomas of the bone, other than osteosarcoma or malignant fibrous histiocytoma: a European Osteosarcoma Intergroup Study. *Eur. J. Cancer* 41, 225–230. <https://doi.org/10.1016/j.ejca.2004.08.026>.
- Pakos, E.E., Grimer, R.J., Peake, D., Spooner, D., Carter, S.R., Tillman, R.M., Abudu, S., Jeys, L., 2011. The “other” bone sarcomas: prognostic factors and outcomes of spindle cell sarcomas of bone. *J. Bone Joint Surg. Br.* 93, 1271–1278. <https://doi.org/10.1302/0301-620X.93B9.27166>.
- Palmerini, E., Jones, R.L., Marchesi, E., Paioli, A., Cesari, M., Longhi, A., Meazza, C., Coccoli, L., Fagioli, F., Asaftei, S., Grignani, G., Tamburini, A., Pollack, S.M., Picci, P., Ferrari, S., 2016. Gemcitabine and docetaxel in relapsed and unresectable high-grade osteosarcoma and spindle cell sarcoma of bone. *BMC Cancer* 16, 280. <https://doi.org/10.1186/s12885-016-2312-3>.
- Palmerini, E., Righi, A., Staals, E.L., 2020a. Rare Primary Malignant Bone Sarcomas. *Cancers (Basel)* 12, E3092. <https://doi.org/10.3390/cancers12113092>.
- Palmerini, E., Setola, E., Grignani, G., D'Ambrosio, L., Comandone, A., Righi, A., Longhi, A., Cesari, M., Paioli, A., Hakim, R., Pierini, M., Marchesi, E., Vanel, D., Pignochino, Y., Donati, D.M., Picci, P., Ferrari, S., 2020b. High dose Ifosfamide in relapsed and unresectable high-grade osteosarcoma patients: a retrospective series. *Cells* 9, E2389. <https://doi.org/10.3390/cells9112389>.
- Palmerini, E., Seeger, L.L., Gambarotti, M., Righi, A., Reichardt, P., Bukata, S., Blay, J.-Y., Dai, T., Jandial, D., Picci, P., 2021. Malignancy in giant cell tumor of bone: analysis of an open-label phase 2 study of denosumab. *BMC Cancer* 21, 89. <https://doi.org/10.1186/s12885-020-07739-8>.
- Paulussen, M., Craft, A.W., Lewis, I., Hackshaw, A., Douglas, C., Dunst, J., Schuck, A., Winkelmann, W., Köhler, G., Poremba, C., Zoubek, A., Ladenstein, R., van den Berg, H., Hunold, A., Cassoni, A., Spooner, D., Grimer, R., Whelan, J., McTiernan, A., Jürgens, H., Study-92, E.I.C.E.S., 2008. Results of the EICESS-92 Study: two randomized trials of Ewing's sarcoma treatment—cyclophosphamide compared with ifosfamide in standard-risk patients and assessment of benefit of etoposide added to standard treatment in high-risk patients. *J. Clin. Oncol.* 26, 4385–4393. <https://doi.org/10.1200/JCO.2008.16.5720>.
- Picci, P., Sangiorgi, L., Rougraff, B.T., Neff, J.R., Casadei, R., Campanacci, M., 1994. Relationship of chemotherapy-induced necrosis and surgical margins to local recurrence in osteosarcoma. *J. Clin. Oncol.* 12, 2699–2705. <https://doi.org/10.1200/JCO.1994.12.12.2699>.
- Picci, P., Vanel, D., Briccoli, A., Talle, K., Haakenaasen, U., Malaguti, C., Monti, C., Ferrari, C., Bacci, G., Saeter, G., Alvegard, T.A., 2001. Computed tomography of pulmonary metastases from osteosarcoma: the less poor technique. A study of 51 patients with histological correlation. *Ann. Oncol.* 12, 1601–1604. <https://doi.org/10.1023/a:1013103511633>.
- Rose, P.S., 2020. What's new in musculoskeletal tumor surgery. *J. Bone Joint Surg. Am.* 102, 2111–2119. <https://doi.org/10.2106/JBJS.20.01510>.
- Rutkowski, P., Gaston, L., Borkowska, A., Stacchiotti, S., Gelderblom, H., Baldi, G.G., Palmerini, E., Casali, P., Gronchi, A., Parry, M., Campanacci, D.A., Scoccianti, G., Wagrodzki, M., Ferrari, S., Dijkstra, S., Pienkowski, A., Grimer, R., 2018. Denosumab treatment of inoperable or locally advanced giant cell tumor of bone - Multicenter analysis outside clinical trial. *Eur. J. Surg. Oncol.* 44 (9), 1384–1390.
- Saylor, R.L., Stine, K.C., Sullivan, J., Kepner, J.L., Wall, D.A., Bernstein, M.L., Harris, M. B., Hayashi, R., Vietti, T.J., 2001. Cyclophosphamide plus topotecan in children with recurrent or refractory solid tumors: a Pediatric Oncology Group phase II study (Pediatric Oncology Group). *J. Clin. Oncol.* 19, 3463–3469. <https://doi.org/10.1200/JCO.2001.19.15.3463>.
- Schuck, A., Ahrens, S., Paulussen, M., Kuhlen, M., Könemann, S., Rube, C., Winkelmann, W., Kotz, R., Dunst, J., Willich, N., Jürgens, H., 2003. Local therapy in localized Ewing tumors: results of 1058 patients treated in the CESS 81, CESS 86, and EICESS 92 trials. *Int. J. Radiat. Oncol. Biol. Phys.* 55, 168–177. [https://doi.org/10.1016/s0360-3016\(02\)03797-5](https://doi.org/10.1016/s0360-3016(02)03797-5).
- Schulz-Ertner, D., Karger, C.P., Feuerhake, A., Nikoghosyan, A., Combs, S.E., Jäkel, O., Edler, L., Scholz, M., Debus, J., 2007. Effectiveness of carbon ion radiotherapy in the treatment of skull-base chordomas. *Int. J. Radiat. Oncol. Biol. Phys.* 68, 449–457. <https://doi.org/10.1016/j.ijrobp.2006.12.059>.
- Shi, W., Indelicato, D.J., Reith, J., Smith, K.B., Morris, C.G., Scarborough, M.T., Gibbs, C. P., Mendenhall, W.M., Zlotecki, R.A., 2013. Radiotherapy in the management of giant cell tumor of bone. *Am. J. Clin. Oncol.* 36, 505–508. <https://doi.org/10.1097/COC.0b013e3182568fb6>.
- Sorensen, P.H., Lessnick, S.L., Lopez-Terrada, D., Liu, X.F., Triche, T.J., Denny, C.T., 1994. A second Ewing's sarcoma translocation, t(21;22), fuses the EWS gene to another ETS-family transcription factor, ERG. *Nat. Genet.* 6, 146–151. <https://doi.org/10.1038/ng0294146>.
- Stacchiotti, S., Longhi, A., Ferraresi, V., Grignani, G., Comandone, A., Stupp, R., Bertuzzi, A., Tamborini, E., Pilotti, S., Messina, A., Spreafico, C., Gronchi, A., Amore, P., Vinaccia, V., Casali, P.G., 2012. Phase II study of imatinib in advanced chordoma. *J. Clin. Oncol.* 30, 914–920. <https://doi.org/10.1200/JCO.2011.35.3656>.
- Stacchiotti, S., Tamborini, E., Lo Vullo, S., Bozzi, F., Messina, A., Morosi, C., Casale, A., Crippa, F., Conca, E., Negri, T., Palassini, E., Marrari, A., Palmerini, E., Mariani, L., Gronchi, A., Pilotti, S., Casali, P.G., 2013. Phase II study on lapatinib in advanced EGFR-positive chordoma. *Ann. Oncol.* 24, 1931–1936. <https://doi.org/10.1093/annonc/mdt117>.
- Stacchiotti, S., Sommer, J., Group, C.G.C., 2015. Building a global consensus approach to chordoma: a position paper from the medical and patient community. *Lancet Oncol.* 16, e71–e83. [https://doi.org/10.1016/S1470-2045\(14\)71190-8](https://doi.org/10.1016/S1470-2045(14)71190-8).
- Stacchiotti, S., Gronchi, A., Fossati, P., Akiyama, T., Alapetite, C., Baumann, M., Blay, J. Y., Bolle, S., Boriani, S., Bruzzi, P., Capanna, R., Caraceni, A., Casadei, R., Colia, V., Debus, J., Delaney, T., Desai, A., Dileo, P., Dijkstra, S., Doglietto, F., Flanagan, A., Froelich, S., Gardner, P.A., Gelderblom, H., Gokaslan, Z.L., Haas, R., Heery, C., Hindi, N., Hohenberger, P., Hornicek, F., Imai, R., Jeys, L., Jones, R.L., Kasper, B., Kawai, A., Krenghli, M., Leithner, A., Logowska, I., Martin Broto, J., Mazzatenta, D., Morosi, C., Nicolai, P., Norum, O.J., Patel, S., Penel, N., Picci, P., Pilotti, S., Radaelli, S., Ricchini, F., Rutkowski, P., Scheipl, S., Sen, C., Tamborini, E., Thornton, K.A., Timmermann, B., Torri, V., Tunn, P.U., Uhl, M., Yamada, Y., Weber, D.C., Vanel, D., Varga, P.P., Vleggeert-Lankamp, C.L.A., Casali, P.G., Sommer, J., 2017. Best practices for the management of local-regional recurrent chordoma: a position paper by the Chordoma Global Consensus Group. *Ann. Oncol.* 28, 1230–1242. <https://doi.org/10.1093/annonc/mdx054>.
- Stahl, M., Ranft, A., Paulussen, M., Bölling, T., Vieth, U., Bielack, S., Görtitz, I., Braun-Munzinger, G., Harges, J., Jürgens, H., Dirksen, U., 2011. Risk of recurrence and survival after relapse in patients with Ewing sarcoma. *Pediatr. Blood Cancer* 57, 549–553. <https://doi.org/10.1002/pbc.23040>.
- Stiller, C.A., Trama, A., Serraino, D., Rossi, S., Navarro, C., Chirilaque, M.D., Casali, P.G., 2013. Descriptive epidemiology of sarcomas in Europe: report from the RARECARE project (RARECARE Working Group). *Eur. J. Cancer* 49, 684–695. <https://doi.org/10.1016/j.ejca.2012.09.011>.
- Valery, P.C., Laversanne, M., Bray, F., 2015. Bone cancer incidence by morphological subtype: a global assessment. *Cancer Causes Control* 26, 1127–1139. <https://doi.org/10.1007/s10552-015-0607-3>.
- van der Heijden, L., Dijkstra, P.D.S., Blay, J.Y., Gelderblom, H., 2017. Giant cell tumour of bone in the denosumab era. *Eur. J. Cancer* 75–83.
- van der Heijden, L., Dijkstra, S., van de Sande, M., Gelderblom, H., 2020. Current concepts in the treatment of giant cell tumour of bone. *Curr. Opin. Oncol.* 32, 332–338. <https://doi.org/10.1097/CCO.0000000000000645>.
- van Doorninck, J.A., Ji, L., Schaub, B., Shimada, H., Wing, M.R., Krailo, M.D., Lessnick, S.L., Marina, N., Triche, T.J., Spoto, R., Womer, R.B., Lawlor, E.R., 2010. Current treatment protocols have eliminated the prognostic advantage of type 1 fusions in Ewing sarcoma: a report from the Children's Oncology Group. *J. Clin. Oncol.* 28, 1989–1994. <https://doi.org/10.1200/JCO.2009.24.5845>.
- Völker, T., Denecke, T., Steffen, I., Misch, D., Schönberger, S., Plotkin, M., Ruf, J., Furth, C., Stöver, B., Hautzel, H., Henze, G., Amthauer, H., 2007. Positron emission tomography for staging of pediatric sarcoma patients: results of a prospective multicenter trial. *J. Clin. Oncol.* 25, 5435–5441. <https://doi.org/10.1200/JCO.2007.12.2473>.
- Vujovic, S., Henderson, S., Presneau, N., Odell, E., Jacques, T.S., Tirabosco, R., Boshoff, C., Flanagan, A.M., 2006. Brachyury, a crucial regulator of notochordal development, is a novel biomarker for chordomas. *J. Pathol.* 209, 157–165. <https://doi.org/10.1002/path.1969>.
- Wagner, L.M., Crews, K.R., Iacono, L.C., Houghton, P.J., Fuller, C.E., McCarville, M.B., Goldsby, R.E., Albritton, K., Stewart, C.F., Santana, V.M., 2004. Phase I trial of temozolomide and protracted irinotecan in pediatric patients with refractory solid tumors. *Clin. Cancer Res.* 10, 840–848. <https://doi.org/10.1158/1078-0432.ccr-03-0175>.

- Whelan, J., McTiernan, A., Cooper, N., Wong, Y.K., Francis, M., Vernon, S., Strauss, S.J., 2012. Incidence and survival of malignant bone sarcomas in England 1979-2007. *Int. J. Cancer* 131, E508–E517. <https://doi.org/10.1002/ijc.26426>.
- Whelan, J., Le Deley, M.-C., Dirksen, U., Le Teuff, G., Brennan, B., Gaspar, N., Hawkins, D.S., Amler, S., Bauer, S., Bielack, S., Blay, J.-Y., Burdach, S., Castex, M.-P., Dilloo, D., Eggert, A., Gelderblom, H., Gentet, J.-C., Hartmann, W., Hassenpflug, W.-A., Hjorth, L., Jimenez, M., Klingebiel, T., Kontny, U., Kruseova, J., Ladenstein, R., Laurence, V., Lervat, C., Marec-Berard, P., Marreaud, S., Michon, J., Morland, B., Paulussen, M., Ranft, A., Reichardt, P., van den Berg, H., Wheatley, K., Judson, I., Lewis, I., Craft, A., Juergens, H., Oberlin, O., Euro-E.W. I.N., 2018. High-dose chemotherapy and blood autologous stem-cell rescue compared with standard chemotherapy in localized high-risk ewing sarcoma: results of euro-E.W.I.N.G.99 and Ewing-2008. *J. Clin. Oncol.* <https://doi.org/10.1200/JCO.2018.78.2516>.
- Whelan, J.S., Davis, L.E., 2018. Osteosarcoma, Chondrosarcoma, and Chordoma. *J. Clin. Oncol.* 36 (2), 188–193.
- Whelan, J.S., Bielack, S.S., Marina, N., Smeland, S., Jovic, G., Hook, J.M., Krailo, M., Anninga, J., Butterfass-Bahloul, T., Böbling, T., Calaminus, G., Capra, M., Deffenbaugh, C., Dhooge, C., Eriksson, M., Flanagan, A.M., Gelderblom, H., Goorin, A., Gorlick, R., Gosheger, G., Grimer, R.J., Hall, K.S., Helmke, K., Hogendoorn, P.C., Jundt, G., Kager, L., Kuehne, T., Lau, C.C., Letson, G.D., Meyer, J., Meyers, P.A., Morris, C., Mottl, H., Nadel, H., Nagarajan, R., Randall, R.L., Schomberg, P., Schwarz, R., Teot, L.A., Sydes, M.R., Bernstein, M., collaborators, E., 2015. EURAMOS-1, an international randomised study for osteosarcoma: results from pre-randomisation treatment. *Ann. Oncol.* 26, 407–414. <https://doi.org/10.1093/annonc/mdu526>.
- Womer, R.B., West, D.C., Krailo, M.D., Dickman, P.S., Pawel, B.R., Grier, H.E., Marcus, K., Sailer, S., Healey, J.H., Dormans, J.P., Weiss, A.R., 2012. Randomized controlled trial of interval-compressed chemotherapy for the treatment of localized Ewing sarcoma: a report from the Children's Oncology Group. *J. Clin. Oncol.* 30, 4148–4154. <https://doi.org/10.1200/JCO.2011.41.5703>.
- Yu, E., Koffer, P.P., DiPetrillo, T.A., Kinsella, T.J., 2016. Incidence, treatment, and survival patterns for sacral chordoma in the United States, 1974-2011. *Front. Oncol.* 6, 203. <https://doi.org/10.3389/fonc.2016.00203>.
- Yu, W., Liu, Z., Tang, L., Lin, F., Yao, Y., Shen, Z., 2017. Efficacy and safety of stereotactic radiosurgery for pulmonary metastases from osteosarcoma: experience in 73 patients. *Sci. Rep.* 7 (1), 17480.
- Zoubek, A., Pfeleiderer, C., Salzer-Kuntschik, M., Amann, G., Windhager, R., Fink, F.M., Koscielniak, E., Delattre, O., Strehl, S., Ambros, P.F., 1994. Variability of EWS chimaeric transcripts in Ewing tumours: a comparison of clinical and molecular data. *Br. J. Cancer* 70, 908–913. <https://doi.org/10.1038/bjc.1994.419>.